

Single Versus Repetitive Traumatic Brain Injury: Current Knowledge on the Chronic Outcomes, Neuropathology and the Role of TDP-43 Proteinopathy

Tamara Janković and Kristina Pilipović*

Department of Basic and Clinical Pharmacology and Toxicology, Faculty of Medicine, University of Rijeka, Rijeka 51000, Croatia

Traumatic brain injury (TBI) is one of the most important causes of death and disability in adults and thus an important public health problem. Following TBI, secondary pathophysiological processes develop over time and condition the development of different neurodegenerative entities. Previous studies suggest that neurobehavioral changes occurring after a single TBI are the basis for the development of Alzheimer's disease, while repetitive TBI is considered to be a contributing factor for chronic traumatic encephalopathy development. However, pathophysiological processes that determine the evolution of a particular chronic entity are still unclear. Human post-mortem studies have found combinations of amyloid, tau, Lewi bodies, and TAR DNA-binding protein 43 (TDP-43) pathologies after both single and repetitive TBI. This review focuses on the pathological changes of TDP-43 after single and repetitive brain traumas. Numerous studies have shown that TDP-43 proteinopathy noticeably occurs after repetitive head trauma. A relatively small number of available preclinical research on single brain injury are not in complete agreement with the results from the human samples, which makes it difficult to draw specific conclusions. Also, as TBI is considered a heterogeneous type of injury, different experimental trauma models and injury intensities may cause differences in the cascade of secondary injury, which should be considered in future studies. Experimental and post-mortem studies of TDP-43 pathobiology should be carried out, preferably in the same laboratories, to determine its involvement in the development of neurodegenerative conditions after one and repetitive TBI, especially in the context of the development of new therapeutic options.

Key words: Alzheimer's disease, Chronic traumatic encephalopathy, TDP-43 proteinopathies, Brain injury, Traumatic

INTRODUCTION

Traumatic brain injury (TBI) occurs as a consequence of the external, mechanical force on the skull, resulting in damage of brain tissue and changes in mental functions [1]. It is an important public health problem and the most common cause of disability and death among young individuals [2, 3], with an incidence in Europe of 262 people per 100,000 population [4]. It was estimated that 50

million people worldwide experience head trauma each year [5, 6] and that almost half of the world's population will develop TBI in their lifetime [7]. Each year, 1.7 million U.S. citizens experience head trauma [8], and it was estimated that there are 3.5 million people with disabilities that came from TBI [9]. The most common causes of brain trauma in the world are traffic accidents (60%), followed by falls (20~30%), violent acts (10%), sports and workplace injuries (10%) [10]. When it comes to long-term consequences, head trauma is known to significantly increase mortality [11-13]. Individuals that sustained TBI have twice the mortality rate in the first year after injury when compared to individuals with similar age, gender and race [14]. It has also been found that TBI shortens life expectancy by an average of 7 years [14]. In the younger popu-

Submitted February 16, 2023, Revised July 18, 2023,
Accepted August 23, 2023

*To whom correspondence should be addressed.
TEL: 385-51-651-242, FAX: 385-51-651-174
e-mail: kristina.pilipovic@uniri.hr

lation, males are more commonly TBI victims (55~80%) than females [15-17]. A possible explanation could be that the most common causes of brain trauma within this age group are traffic injuries, violent activities and sports injuries, or activities that significantly involve the male population. In the elderly population, the most common cause of TBI are falls, where the proportion of male and female patients is equal [16]. Also, lower socioeconomic status, previous psychiatric disorders, and/or prior drug use, increase the risk of TBI development [18].

The severity of TBI is commonly assessed based on clinical symptoms using the Glasgow Coma Scale (GCS), which can subclassify brain trauma into mild (GCS scale 13~15), moderate (GCS scale 9~12) and severe (GCS scale <9) [19]. Clinical assessment using GCS has been in use for more than 45 years [20, 21] and benefits general practitioners and specialists in assessing patient recovery [16, 22, 23]. However, some researchers believe that the post-traumatic amnesia (PTA) is a better TBI severity predictor [24] with the first studies by Russell and Smith [25] concluding that PTA lasting less than an hour is a characteristic of mild, PTA duration 1~24 hours of moderate and PTA of 1~7 days of severe brain trauma. Regardless of the method of assessing the severity of TBI, the most common is mild (81%), followed by moderate (11%) and severe (8%) [26]. Moderate and severe brain traumas most often occur after traffic accidents and falls [4]. Mild TBI is often repetitive and occurs in athletes involved in contact sports [27, 28], military personnel [29, 30] and victims of domestic violence [31, 32]. Mild TBI, also known as concussion [33], often goes unrecognized because 90~95% of cases resolve on their own within 10 days [34]. However, each subsequent TBI increases the risk of brain damage and the development of neurological disorders [33]. TBI is significantly different from injury to any other organ because it leads to chronic changes in the brain and other organs [35].

Whether a person has acquired one or more TBIs, acute brain tissue damage will frequently lead to the development of long-term neurological disorders [33, 36], including posttraumatic epilepsy [35, 37] and sleep disorders such as hypersomnia [38]. Epidemiological studies have shown that TBI is a possible risk factor for the development of neurodegenerative diseases such as Alzheimer's and Parkinson's disease, amyotrophic lateral sclerosis (ALS), frontotemporal lobar degeneration (FTLD) [39] and chronic traumatic encephalopathy (CTE) [40]. Also, neuroendocrine disorders are common (e.g. hypopituitarism [41]), as are psychiatric disorders, such as obsessive-compulsive disorder, anxiety, mood swings, depression, addictions, and suicide [35, 42]. In addition to neurological, several non-neurological disturbances occur as a result of brain trauma: sexual dysfunction (including hypogonadism, muscle weakness, and osteoporosis [43]), bladder and bowel

incontinence [44], and musculoskeletal dysfunction [45], fractures [44] and metabolic dysfunctions (abnormalities in amino acid metabolism, which may have an impact on some neurological consequences [35]).

PATHOPHYSIOLOGICAL AND PATHOLOGICAL PROCESSES DETERMINING THE OUTCOME OF TRAUMATIC BRAIN INJURY

Primary brain injury

Traumatic brain injury is a complex condition that begins with a primary injury, while secondary injury develops over time [46, 47]. Primary injury occurs due to the action of the mechanical force on the brain matter directly below the site of trauma, which causes tissue and cerebral vasculature damage [48], and it can result in focal or diffuse injury [49].

Focal TBI includes intracranial hematomas (subdural and epidural), skull fractures, lacerations, contusions, and penetrating wounds [47, 50]. Diffuse TBI causes a wider distribution of injury with intact vascular and neural pathways [22]. Diffuse injury also causes deregulation of the cytoskeleton, axonal cell membranes and axonal transport mechanisms [51, 52], but it does not entail damage of the entire brain as the axonal damage is mostly localized in the brainstem, the parasagittal white matter of the cortex, corpus callosum, and grey and white matter of the cerebral cortex [53, 54]. Intriguingly, computed tomography and magnetic resonance imaging, when performed immediately, rarely reveal any abnormalities after mild diffuse brain trauma [53, 55]. Although focal and diffuse injuries are usually described separately in the literature, clinically, TBI most commonly occurs as a combination of both focal and diffuse injury [49].

Secondary brain injury

Primary traumatic brain injury is irreversible [56] and cannot be affected by pharmacological interventions, but within few minutes commences the activation of cellular processes included in the secondary injury [47]. These cellular processes contribute further to brain tissue damage in the following days, months, and even years after the trauma [57, 58]. This includes the excessive release of glutamate, overload of the released Ca^{2+} , excitotoxicity, oxidative stress, inflammation and mitochondrial dysfunction [19, 47, 57, 59]. Cellular changes resulting from secondary injury contribute to additional neuronal damage and synaptic dysfunction [48, 60-62].

Mechanical injury of blood vessel walls activates the coagulation cascade with consequent cerebral ischemia at the impact site [63-65]. Mechanical force during the primary injury predominantly

causes damage to the cell membranes of neurites and axons, while perikaryons and myelin sheaths are considered more protected [66, 67]. Brain trauma causes a short imbalance in a physiologically precisely regulated cell membrane [68]. In the acute phase after trauma (within the first hour), an excessive number of neurotransmitters, primarily excitatory amino acids (mostly glutamate), are released from the presynaptic nerve endings, resulting in the activation of corresponding receptors at postsynaptic terminals, such as N-methyl-D-aspartate (NMDA) and α -amino-3-hydroxy-5-methyl-4-isoxazole-propionic acid (AMPA) receptors to which glutamate binds, causing the changes in K^+ , Na^+ and Ca^{2+} transmembrane conductance [69, 70]. Under these conditions, ATPase pumps rapidly utilize reserves of cellular ATP in an effort to return the membrane potential to equilibrium [19, 71, 72].

Simultaneously with the release of K^+ after TBI, there is an accumulation of intracellular Ca^{2+} [73], which accumulates excessively in mitochondria, thus affecting its function and consequently inducing oxidative stress [19, 74, 75]. In addition, high levels of intracellular Ca^{2+} cause activation of numerous cellular enzymes such as phospholipases that damage cells, proteases that destroy the cytoskeleton, and endonucleases that trigger apoptosis and necrosis by initiating DNA fragmentation [70, 76]. Inflammation is considered one of the crucial processes of secondary brain injury [57, 77, 78]. Microglial cells, the residual cells of the brain's immune system, are the first cell type activated after trauma, followed by the activation of astrocytes and endothelial cells [57, 79]. Due to the damaged blood brain barrier (BBB), the cells of the innate, and then the acquired peripheral immune system, infiltrate the brain [22, 57]. Neuroinflammatory processes can last for years after TBI and promote neurodegeneration [80, 81]. The ultimate mechanisms of brain trauma include initiating cell death of neurons and glial cells [82]. Neuron death can occur by necrosis, a passive process that results from the irreversible loss of ionic balance, the accumulation of water in cellular organelles, which ends in cell rupture [83]. However, a cell can also initiate programmed cell death processes that involve energy expenditure [70, 83].

Role of neuroinflammation in the posttraumatic pathology

The central nervous system (CNS) responds to brain trauma by a local reaction and residual immune cells activation [22, 57, 84] but also by a systemic immune response [78]. Although the CNS, unlike other organs, does not have classical lymphatic drainage, functional lymphatic vessels that can contribute to the development of neuroinflammatory and neurodegenerative changes were found in the sinus of the dura mater [85].

The cascade of immune activities that begins with TBI is commonly referred to as sterile immune response [86]. Lagraoui et

al. [87] found that different levels of brain trauma activate the expression of similar gene profiles among mild and severe TBI. This finding suggests that, regardless of the intensity of the trauma, a common, nonspecific type of immune response is activated [86]. However, the pathophysiology of neuroinflammation is still unclear and previous studies have shown that inflammation after TBI can act both harmful and neuroprotective [61, 88, 89]. Further studies of neuroinflammation and the use of immunomodulatory drugs after TBI are necessary because they could completely change the clinical outcome in patients [45, 77].

After a few minutes from trauma-induced meningeal damage, astrocytes release signaling molecules called alarmins that include chemokines, heat shock proteins and ATP molecules [57, 88, 90]. Alarmins bind to sensory receptors, such as Toll-like receptors or purinergic receptors, located on resident immune system cells, microglial cells and inflammasomes [57, 78, 91]. Inflammasomes are multiprotein oligomers that are expressed in myeloid cells and can, as part of the innate immune system, stimulate the production of proinflammatory cytokines, such as interleukins IL- 1β and IL-18 [78, 88, 92, 93].

Brain trauma of different severities can cause the proliferation and activation of astrocytes which is referred to as astrogliosis [91, 94, 95]. Reactive astrocytes have changed morphology and are transformed into a hypertrophic state with increased glial fibrillary acidic protein (GFAP) expression [91, 94, 96, 97]. Astrocytes play an essential role in the clearance of TBI generated debris [96] and are considered fast responders to injury by creating the aforementioned signaling molecules [57]. Formation of the astroglial scar is essential for brain tissue protection, function preservation and clearance of damaged tissue after TBI [91, 98, 99]. Excitotoxicity could be deteriorated by astrocytic excessive release of various proinflammatory molecules, but also because of their reduced capacity of glutamate buffering. Namely, reduced EAAT1 and 2 expressions have been detected in the human [100-102] and animal TBI samples [103, 104], and could contribute excessive glutamate concentration which promotes neuronal cell death [91]. Reduction in the EAAT2 transporter is also regulated by the nuclear factor kappa B (NF κ B) pathway and reduction in potassium channel expression [105, 106], which could also contribute the neuroinflammation. Also, GFAP breakdown products released into serum have demonstrated a significant predictive ability of injury severity [107].

Microglial cells are highly branched resident immunological cells that have fine mobile appendages for moving and continuous search of the brain parenchyma for danger signals [108]. Numerous receptors are used for this purpose, such as TLR and NLR receptors, receptors for ATP, glutamate, cytokines and growth

factors [109]. Microglia spread collected information with neurons, but also astrocytes and oligodendrocytes [110, 111]. After experimental [97, 112] and human [58, 112] TBI, microglia will undergo a complex transformation into its activated form, which is characterized by changes in morphology, biochemical composition and function, depending on the injury type and severity [91]. Microglia become ramified and increase in size [113] as they migrate to the trauma site [91]. Depending on the received stimuli, microglia can be activated into M1 or M2 polarization phenotypes [113]. M1 phenotype is considered proinflammatory, as this type of cell secretes proinflammatory cytokines, such as IFN- γ , TNF- α , and IL-1 β [91, 113]. Several M2 subtypes (M2a, M2b, M2c) show complex signaling by promoting both anti-inflammatory and proinflammatory responses [91, 109, 112, 113]. However, the aforementioned polarization of microglia is extremely simplified, as it has been shown by transcriptomic analyzes that revealed complex additional polarization states of microglia [114]. In chronic conditions such as TBI, it is very difficult to discriminate the M1/M2 microglial response, and brain trauma studies have detected simultaneous M1 and M2 expression [109]. Also, microglia can secrete extracellular vesicles containing inflammatory molecules and spread the inflammation, as has been found in the CSF of TBI patients [91, 115].

In the first few minutes to hours after TBI, microglial cells activate the NF κ B pathway [116], leading to excessive production of cytotoxic factors, such as nitric oxide, IL-1 β , and TNF α [117], which contribute to neuronal cell death [118]. Also, the NF κ B signaling pathway promotes inflammation by producing chemokines, cytokines, reactive oxygen species (ROS) and reactive nitrogen species (RNS) that contribute to further damage of the brain tissue [80, 119, 120].

Due to the BBB damage, peripheral immune cells can enter brain tissue, and neutrophils are considered the first peripheral immune cells to accumulate in meninges and perivascular tissue and enter the trauma-damaged brain [77, 78, 88, 90]. At this stage, the complement system is also activated [78, 121, 122]. In the next step, but within the first 48 hours of the primary injury, T lymphocytes and monocytes begin to accumulate at the site of damage with T lymphocytes producing anti-inflammatory cytokines that counteract the action of alarmins and act neuroprotective [88, 123, 124]. Monocytes transformed into macrophages remove the debris and damaged cells [57, 79, 88], but they, together with microglial cells, can cause further damage or resolution of the inflammatory process with tissue regeneration [91]. Damaged neurons can present antigens to antigen-presenting cells and T lymphocytes [90] that, at best, can lead to the resolution of the inflammatory response with the formation of trophic factors and glial scarring [91].

However, after TBI, chronic neuroinflammation may persist [57]. Namely, Ramlackhansingh et al. [125] found microglia activity in patients who survived TBI as many as 17 years after the primary injury.

A cascade of neuroinflammatory processes begins right after single brain trauma [77]. Acute inflammation after brain trauma significantly contributes to the overall pathology, but its protective and regenerative role is also important [58]. Neuroinflammatory processes in some survivors are not resolved in the acute phase after the initial trauma but can develop for years, regardless of its severity [64, 77]. A study by Gentleman et al. [126] confirmed microglial activity in a limited number of patients who survived more than one year from the initial trauma. Johnson et al. [58] reported that 28% of patients who survived more than one year after TBI have active microgliosis in the white matter of the corpus callosum. Interestingly, activated amoeboid microglia in this study was not observed in subjects with acute TBI. Also, an increase in microglia activity in the corpus callosum has been reported immunohistologically in a patient who survived 18 years after TBI [58]. Positron emission tomography showed microglial activity 17 years after focal TBI, bilaterally, in regions distant from the initial site of trauma, such as the thalamus, putamen, occipital cortex, and hind limb of the inner capsule of the brain, but not at the injury site and corpus callosum [125]. Differences in regional microglial activity between studies can be explained by differences in the groups of patients examined and the characteristics of the injuries sustained. It is important to note that microglial activity after brain trauma must be carefully interpreted in as many subjects as possible, because some studies have shown variable microglial activity, i.e., a certain degree of presence of activated microglia in the control group, especially in the elderly [127]. Neuroinflammation after single head trauma can occur in the brain tissue, but inflammatory processes have also been recorded in the periphery [77, 128, 129]. Due to TBI and compromised BBB, elevated levels of cytokines and chemokines in the brain can lead to a stronger peripheral immune response [130, 131], which can then re-regulate the immune response in brain tissue [130, 132, 133]. Recent studies that analyzed the serum or cerebrospinal liquor (CSL) of patients exposed to a single trauma confirm chronically elevated levels of proinflammatory cytokines and associate this proinflammatory milieu after TBI with posttraumatic stress disorder and suicidal thoughts [134, 135]. The described chronic inflammatory processes also contribute to the development of neurodegeneration and consequent dementia [58, 136].

Neuroinflammatory processes have also been reported in individuals who have developed CTE as a result of repetitive trauma [137]. Microglial cells are activated already after single brain

Table 1. Comparison of the chronic cellular, molecular, and clinical pathophysiological changes after single and repetitive TBI

Pathophysiological chronic changes		
Both single and repetitive brain trauma lead to development of long-term neurological disorders [33, 35, 36, 39, 80, 81], depending on the extent of the acute injury		
Single TBI (sTBI)		
Cellular	Molecular	Clinical
Glial scarring [91] Hyperactivated microglia [77, 125, 126]	Accumulation of β -amyloid plaques [142-145], mostly in grey and less in white brain matter [142], predominantly with fibrillar characteristics (such as seen in developed Alzheimer's disease) [137, 146] and possible genetic predisposition risk [142, 147] Neurofibrillary tangles (NFT) with a distribution that matches the one in Alzheimer's disease [141, 148] Accumulation of α -synuclein in some patients [149, 150] Loss of synapses and progressive neuronal deficit [142, 151] TDP-43 proteinopathy? [56, 152, 153]	Generalized brain atrophy [137, 154, 155] includes entire brain parenchyma (including the frontal), grey and white matter of the cerebrum, cerebellum, and brainstem [155] with volume reduction of corpus callosum [58, 156] Cognitive disorders [157] depending on the degree of degenerated anatomical structures [158] Increased Alzheimer's disease risk [136, 159, 160]
Repetitive TBI (rTBI)		
Cellular	Molecular	Clinical
Tau deposits in astrocytes and neurons [161, 162] Hyperactivated microglia [77]	Hyperphosphorylated tau protein aggregates (NFTs) in the cortical sulci, perivascular regions of the frontal lobe, midbrain, thalamus, basal ganglia, amygdala and hippocampus [137, 163] Beta-amyloid aggregates and Lewis bodies present in some patients [137, 164] TDP-43 proteinopathy [152, 154, 164-166]	Localized brain atrophy detected in the frontal and temporal part of the cortex and the cerebellum [137, 167]; atrophy of the hippocampus and amygdala and entorhinal cortex [40, 138, 168, 169] Enlargement of the cavum septum pellucidum [40, 170, 171], with occasional absence of the septum or its separation from the fornix and the corpus callosum [40, 137, 171-176] Cognitive dysfunction [168, 169, 177] with pyramidal, extrapyramidal, and cerebellar dysfunction observed [137] Increased CTE risk development [164]

trauma, and it is to be expected that each subsequent trauma, including the mild form, will cause additional hyperactivation of microglia, additional release of cytokines, chemokines and other proinflammatory mediators, and consequent neurodegeneration [77]. Postolache et al. [77] have elaborated a double hit model that explains TBI as a priming event in which microglia becomes activated and forms a foundation for an increased inflammatory response after sustaining the subsequent injury. Repetitive brain trauma could prevent the transition of microglia from the pro-inflammatory state (M1) to the neuroprotective state (M2) [77]. This could explain why mild repetitive brain trauma, even when the next trauma occurs after several months, can cause a higher incidence of prolonged neurological consequences compared to a single brain trauma [138]. As after a single TBI, repetitive TBI is associated with chronic neuroinflammation and the consequent development of neurodegenerative changes [137-139]. The final extent of neuroinflammatory changes depends on the intensity and time interval between each individual brain trauma [77]. Repetitive brain trauma experienced by military personnel is also

associated with elevated proinflammatory cytokines in serum and the development of more severe forms of post-traumatic stress disorder [140]. Cellular and molecular comparison changes after single and repetitive TBI are shown in Table 1 [33, 35, 36, 39, 40, 56, 58, 77, 80, 81, 91, 125, 126, 136-138, 141-177].

Gross neuropathological changes in traumatic brain injury

Brain atrophy refers to the loss of cells or connections between cells, resulting in reduced functionality of brain tissue [178]. Volumetric studies have shown that generalized brain atrophy develops among the degenerative changes after a single TBI [137, 154, 155]. Already after a mild TBI, generalized progressive atrophy rapidly develops and involves the entire brain parenchyma (including the frontal areas), grey and white matter of the cerebrum, cerebellum, and brainstem [155]. Johnson et al. [58] detected a 25% reduction in corpus callosum thickness in patients who survived more than one year after a single TBI confirming progressive tissue loss. Tomaiuolo et al. [156] published comparable results, as they observed a progression in volume reduction of corpus callosum eight years

after the trauma, compared to the volume recorded one year after the initial insult. Also, studies have shown that memory test results correlate with the degree of degenerated anatomical structures, such as the left and right hippocampus, corpus callosum and fornix, suggesting diffuse injury characteristics, neural degeneration, and loss of neural connections after TBI [158]. These changes develop over years and affect the final recovery and reintegration of the patient into everyday life.

Conversely, in boxers with acquired CTE as a consequence of repetitive TBI, localized brain atrophy was noted in the frontal and temporal part of the cortex and the cerebellum [137, 167]. Significant regional atrophy of the hippocampus and amygdala with concomitant cognitive dysfunction has been reported in professional American football players [168, 169]. In other athletes exposed to recurrent brain traumas, few cases of generalized atrophy have been reported, which is to be investigated further [137]. The most significant atrophy in the later stages of CTE was noted in the entorhinal cortex, hippocampus, and amygdala [40, 138, 168]. Enlargement of the *cavum septum pellucidum* (CSP) is the most common *post-mortem* finding in individuals who have developed CTE [179], which also arises as a consequence of repetitive traumas [40, 170, 171]. Although observed in 64 to 99% of cases, the mechanism by which CSP develops is still unclear. One of the assumptions is that CSP arises from atrophy of the cerebral cortex with ventricular dilatation, also a typical neuropathological finding in CTE. Another hypothesis is that CSP develops due to repeated increases in intracranial pressure which, in addition to increasing the septum, also cause ventricular dilatation [137]. In some cases, fenestrated septum or hydrocephalus were detected in addition to CSP [40]. Occasionally, the absence of the septum or its separation from the fornix and the corpus callosum are observed [40, 137, 171-176]. CSP can be detected noninvasively, radiologically, in individuals exposed to repetitive trauma [180], and increased CSP has also been observed in neuropsychiatric disorders such as schizophrenia, posttraumatic stress disorder, and obsessive-compulsive disorder [181]. Interestingly, increase of the CSP has not been observed in individuals who have survived a single brain trauma [137]. Comparison of the gross neuropathological changes after single and repetitive TBI are also shown in Table 1 [33, 35, 36, 39, 40, 56, 58, 77, 80, 81, 91, 125, 126, 136-138, 141-177].

CHRONIC NEUROPATHOLOGY AFTER SINGLE VERSUS REPETITIVE TRAUMATIC BRAIN INJURY – SIMILARITIES AND DIFFERENCES

Chronic neuropathological changes after single and repetitive TBI are highly heterogeneous and individual concerning the ac-

quired trauma. However, they also share some common clinical symptoms, which classify them as neurodegenerative disorders [58, 68, 77, 137]. According to the classical view, dominant in the scientific literature, the spectrum of chronic and neurobehavioral symptoms after a single TBI is considered to be the basis for the Alzheimer's disease development [159], and the symptoms of repetitive TBI are thought to be connected with the development of CTE [164]. However, studies have shown some overlaps in the clinical presentation of symptoms, regardless of the TBI type acquired during life [164, 182, 183].

Numerous epidemiological studies have shown that even after only one moderate or severe brain trauma, the risk of developing progressive cognitive dysfunctions increases, which ultimately leads to the development of dementia [137, 157, 159, 160, 180, 184, 185]. People who have experienced a single TBI during their lifetime have an increased incidence of Alzheimer's disease and other dementias, and generally, dementias occur earlier in life in these patients [136, 160], as it is shown in Table 1 [33, 35, 36, 39, 40, 56, 58, 77, 80, 81, 91, 125, 126, 136-138, 141-177]. A pathobiological link between Alzheimer's disease and a single brain trauma was first established when it was found that TBI causes early and rapid accumulation of β -amyloid plaques in the brain [142-145]. The pathology of Alzheimer's disease is characterized by senile plaques, neurofibrillary tangle (NFT), loss of synapses and progressive neuronal deficit [142, 151], while gliosis, chronic inflammation, excitotoxicity and oxidative stress, characteristics of secondary TBI, may contribute to its progression [145, 186]. Namely, senile plaques in Alzheimer's disease predominantly develop in the elderly, while the occurrence of senile plaques after a single TBI is observed in all age groups and within a few hours after TBI, mostly in grey and less in white brain matter [142]. Acute senile plaques after a single TBI show diffuse characteristics, just like those found in the early stages of Alzheimer's disease, while in long-term survivors after TBI, fibrillar plaques, characteristic of developed Alzheimer's disease, are predominantly observed [137, 146]. The $A\beta_{42}$ peptide is the dominant peptide form found in plaques, and it is also prone to aggregation [142, 187]. Although these findings have been confirmed by numerous studies [184], a consensus has not been reached, mostly because some epidemiological studies have not revealed a clear link between TBI and the Alzheimer's disease [188, 189], which is most likely due to smaller case numbers or reliance on retrospective findings of patients unable to remember whether they have experienced TBI or not [142]. The connection between Alzheimer's disease and TBI has been supported by the genetic predisposition related to the apolipoprotein E protein (APOE). Namely, it was found that individuals who survive TBI and carry the APOE ϵ_4 allele, have a more severe outcome of Alzheimer's dis-

ease [142, 147]. The acute occurrence of NFTs, as well as aggregates of phosphorylated tau protein, i.e., 4 weeks after brain trauma, has not been detected [190]. However, in 30% of the subjects who survived one TBI for more than a year, NFTs were found with a distribution that matches the one in Alzheimer's disease [141, 148]. In a small number of patients who survived more than a year after brain trauma, NFTs were found in the depths of the sulci, which is considered a finding more common for repetitive TBI [141]. Single moderate to severe TBI can be associated with individual coexistence of multiple proteinopathies, such as α -synuclein and β -Amyloid, depending on the acquired type of injury [149, 150].

It remains controversial whether a single brain trauma can cause CTE pathology, but some studies suggest such findings [153, 172]. Also, CTE pathology has been identified in some cases without a history of repetitive TBI, i.e., in drug addicts [191], individuals with temporal lobe epilepsy [192] and as a comorbidity with other neurodegenerative diseases [164, 193]. Along with the association of single TBI and dementia, Plassman et al. [157] found a dose-response relationship, i.e., a higher risk of dementia developing in persons who survived one severe TBI, while the ones who survived one moderate TBI were at a lower risk. Loss of consciousness after one brain trauma is a risk for dementia progress, compared to those who have not lost consciousness [137, 185].

The appearance of neurocognitive and motor symptoms after repetitive head traumas were first recorded in 1928 in retired boxers by Martland [194], and this syndrome was termed "punch drunk". Repetitive TBI research in boxers was continued by Millspaugh [195], who in 1937 replaced the existing term with "*dementia pugilistica*" (dementia of professional boxers), due to consequently developed cognitive problems. However, individuals not associated with boxing but exposed to mild repetitive TBI, such as athletes participating in other contact sports (i.e., American football, wrestling, ice hockey, etc.), victims of domestic violence, and military personnel, showed consistent neuropathological findings [137]. In order to terminologically expand the name for the described progressive neuropathological findings, Omalu et al. [173] first established the idea of CTE, based on the evidence from the analyses of brains of the professional American football players. In 2016, neuropathological criteria for CTE has been defined: accumulation of hyperphosphorylated tau protein in astrocytes and neurons surrounding small blood vessels at the depths of cortical sulci [161, 162]. Symptoms include emotional instability with personality changes, memory difficulties with dementia, aggression, depression, and suicidal thoughts [196], as it is indicated in Table 1 [33, 35, 36, 39, 40, 56, 58, 77, 80, 81, 91, 125, 126, 136-138, 141-177]. The symptoms of CTE are very similar to those seen in other dementias, particularly Alzheimer's disease, which complicates

its clinical diagnosis [183]. Currently, the most reliable diagnosis is based on *post-mortem* tissue analysis [196]. CTE is considered a tauopathy manifested by the presence of hyperphosphorylated tau protein aggregates, or NFTs [197], which, along with β -amyloid plaques, are considered primary markers of Alzheimer's disease [163]. NFTs are the most commonly described pathohistological finding, even in the earliest reported cases of CTE, and have been recorded in the cortical sulci, perivascular regions of the frontal lobe, midbrain, thalamus, basal ganglia, amygdala and hippocampus [137, 163]. The composition and structure of NFTs do not differ in CTE and Alzheimer's disease, but there are differences in the early distribution of the described aggregates [163]. Hof et al. [198] were the first to describe the finding of a hyperphosphorylated tau protein in the sulci depths of layers 2 and 3 of the neocortex in an autistic patient who injured himself by hitting his head. The brain sulci show sensitivity to the biomechanical consequences of trauma and are considered a pathognomonic finding of CTE [137, 198]. However, McKee et al. [164] found, and other studies in a similar proportion confirmed [137], that in 47% of subjects diagnosed with CTE, in addition to NFTs, some other pathological characteristics appear, e.g., beta-amyloid aggregates, Lewi's bodies and TDP-43 proteins whose roles in the pathogenesis of CTE have yet to be defined. It has also been detected that accumulation of TDP-43 is greater with increased staging of CTE [199]. Following repetitive TBI, pyramidal, extrapyramidal, and cerebellar dysfunction were observed [137]. As well as after a single brain trauma, a small number of repetitive trauma studies have shown an association between "dose and response" in cognitive dysfunction [177] and radiological findings [170]. These may suggest that professionals exposed to repetitive TBIs have a higher risk of developing CTE and subsequent neurodegenerative changes than individuals who are less frequently exposed to recurrent head traumas [137].

THE ROLE OF TAR DNA-BINDING PROTEIN 43 PROTEINOPATHY IN THE CHRONIC POSTTRAUMATIC BRAIN CHANGES

TDP-43 is a ubiquitous DNA and RNA binding protein of 43 kDa with many physiological functions [200]. It regulates alternative excision, microRNA formation, mRNA translation and stability, and the life cycle of long noncoding RNAs [201-203]. TDP-43 is primarily found in the nucleus, but because of its involvement in nuclear transport regulation and tracking of the newly transcribed mRNA, it is also found in the cytoplasm as part of cytoplasmic mRNA ribonucleoprotein (RNP) granules [149, 204]. Studies have shown that TDP-43 binds to more than 6,000 different RNA molecules, or 30% of the total transcriptome, indicating its importance

in mRNA metabolism, including mRNAs important in synaptic function and plasticity [205]. Disturbances in TDP-43 expression and localization can lead to deregulation in synaptic transmission, which may be an early indicator of cognitive dysfunctions such as those occurring in ALS and FTLD [204, 206, 207], and it is relevant to note that synaptic toxicity is one of the early signs of neurodegeneration and present in both Alzheimer's [208] and Parkinson's disease [209].

Most cases of ALS are sporadic (90~95%), and about 97% of sporadic cases of ALS includes inherited mutation in the TARDBP gene [210]. The remaining 5~10% of ALS cases are familial ALS in which only 5~10% of patients have a TARDBP gene mutation [210, 211]. Also, it was estimated that 50% of FTLD cases are caused by a mutation in the TDP-43 gene [212, 213]. TDP-43 aggregates are often present in dementia with Lewy bodies, and Alzheimer's, Parkinson's, and Huntington's disease as a secondary histopathological feature [200, 203]. The discovery of the TDP-43 pathological characteristics in various multisystem disorders has led to the development of the concept of TDP-43 proteinopathy [213]. It has been found that in FTLD and ALS, TDP-43 from neurons and glia translocates permanently into the cytoplasm, where it undergoes the processes of hyperphosphorylation and ubiquitination with the formation of cell inclusions, which is considered a key characteristic of TDP-43 proteinopathy [39, 200, 207, 213-215]. An additional feature of TDP-43 proteinopathy is the cytoplasmic cleavage of TDP-43 into C-terminal fragments of 20~25 kDa and 35 kDa size, which can also be phosphorylated, ubiquitinated, and eventually built in cytoplasmic aggregates [210, 216, 217]. Some studies have shown that these fragments can be neurotoxic and cause consequent cell death [39], while other studies consider these fragments to be part of the cell's physiological response to an overall increase in cytoplasmic TDP-43 [212].

The cellular processes that cause TDP-43 proteinopathy have not been fully elucidated, but it was found that lipopolysaccharide-induced inflammation can cause TDP-43 translocation and aggregation *in vitro* and *in vivo* [218]. Also, neurodegeneration and cell death can occur after TDP-43 translocation caused by axotomy [165]. It has been recently noted that *in vivo* TDP-43 knockdown reduces neuroinflammatory and neuropathological changes [219].

Previous research has shown similarities in the pathological changes of amyloid-beta and tau protein after single and repetitive TBI, while differences in TDP-43 proteinopathy have thus far been poorly investigated. All the known TDP-43 differences after single and repetitive TBI are based on the degree of phosphorylation and translocation of TDP-43 in the cytoplasm, which are considered as key steps in the development of further pathologies.

One of the few studies that suggest the difference in TDP-43

proteinopathy after one and repetitive TBI is the study by Johnson et al. [152]. The authors immunohistologically analyzed numerous brain regions of 23 acute (less than 14 days) and 39 long-term (1~47 years) survivors of single, moderate to severe TBI to determine the presence of TDP-43 proteinopathy. Analyses included the hippocampus, medial temporal lobe, cingulate gyrus, superior frontal gyrus, and brainstem. The phosphorylated form of TDP-43, which is thought to be responsible for inclusion formation and altered DNA interaction, was found only in 3 of the 62 tested patients, and it was concluded that single brain trauma does not lead to the development of TDP-43 aggregates even in the long-term survivors. However, in the same study, increased levels of cytoplasmic TDP-43 were detected in almost all *post-mortem* samples of acute (86.9%) and long-term single TBI survivors (71.8%), with the cortex as the most prevalently affected region in the analyzed groups. Diffuse cytoplasmic TDP-43 staining indicated a change in neuronal morphology with shrinkage and an angular appearance of the perikaryon. The authors believe that the enhanced cytoplasmic expression of TDP-43, with the absence of aggregate formation after single brain trauma, is a consequence of a physiological, rather than a pathological response to injury. What needs to be added is that some researchers question the determination of phosphorylated proteins in human *post-mortem* tissue due to the observed rapid degradation of numerous phosphorylated forms [220, 221]. Further on, a case study by Tribett et al. [153] reported one long-term surviving patient (42 years) with TDP-43 immunoreactivity in the perikaryon and cytoplasmic inclusions after a single severe TBI. It is interesting to note that the mentioned case of one TBI was characterized as CTE, due to the presence of phosphorylated tau protein, which also showed colocalization with TDP-43. Also, TDP-43 immunoreactivity was found at the marginal parts of the damaged tissue, in the penumbra, suggesting that TDP-43 deregulation is part of the secondary injury. Phosphorylated TDP-43 fragments of 35 and 25 kDa, but only in the nuclei were found in a study by Tan et al. [56] that involved only six patients surviving up to 3 days after the brain trauma whose severity was not determined. In these studies, disturbed nucleocytoplasmic distribution was observed, and that could be important for the development of TDP-43 cytoplasmic aggregates and the consequent neuropathological clinical profile. However, further research is necessary to confirm this, especially in the field of experimental brain trauma [222]. The changes in the TDP-43 expression, intracellular localization and modifications after single and repetitive TBI are shown in Fig. 1 [56, 152, 153, 165, 166, 220, 223-226].

When it comes to determining severity and predicting recovery after TBI, biomarkers in the CSL and plasma are increasingly used

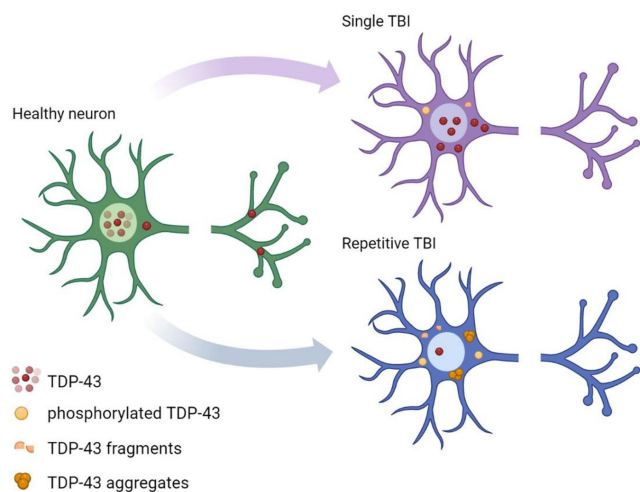


Fig. 1. The changes in the TDP-43 expression, intracellular localization, and modifications of neurons under the conditions of single and repetitive TBI. Single TBI induces abundant TDP-43 translocation from the nucleus to the cytoplasm [223, 224]. Fragmentation [224] and phosphorylation of TDP-43 [56, 153, 220, 223] in the cytoplasm are poorly pronounced, with the lack of aggregates. After repetitive brain trauma, TDP-43 shows abundant aggregation in the cytoplasm [165, 166, 225] which is accompanied by its fragmented [224, 226] and phosphorylated forms [152, 220, 226].

[227-229]. A translation study by Yang et al. [230] was the first to establish the presence of TDP-43 and degradation products of 35 and 25 kDa in human CSF 24 hours after one severe TBI. The presence of these TDP-43 fragments in the blood after TBI was also confirmed [231]. Further research is needed to conclude the association of these biomarkers with the number of brain traumas and their severity.

In experimental brain trauma research, the results from the limited number of studies differ depending on the used models and the severity of the injury. In an *in vitro* neuronal cell culture model of a mild TBI, the accumulation of the phosphorylated and ubiquitinated TDP-43 cytosolic aggregates was demonstrated, suggesting a consequential effect on neuronal function [220]. Also, it was shown that after two traumas, the amount of the phosphorylated cytosolic TDP-43 increases more than two times, and by more than three times after three traumas [220]. In an animal stab injury focal brain trauma model in the motor cortex, an increase in phosphorylated TDP-43 inclusions three and seven days after injury with a return to basal values 40 days after TBI was observed immunohistologically [232]. It is interesting to note that the authors of the same study, using Flierl's [233] weight drop model of diffuse brain trauma on the exposed skull, came to opposite results because phosphorylated TDP-43 granules [232] were not recorded at the same time points. That indicates that this type of injury plays an important role in the development of TDP-43 proteinopathy.

Wiesner et al. [232] compared the effect of single and repetitive focal stab brain injury and on the third day after repetitive TBI observed more phosphorylated TDP-43 inclusions comparing to the single TBI. In an experimental focal brain trauma, using Feeney's weight drop model to the forebrain, Huang et al. [234] demonstrated TDP-43 proteolysis and astrocyte hypertrophy. Namely, in cell lysates from the injury site, an increase in TDP-43 fragments of 25 kDa size on the seventh day and 35 kDa on the third and seventh day after trauma was detected, with a concomitant decrease in total cell TDP-43 on the first, third and seventh day after TBI. Using urea fractions, aggregation of these fragments was recorded seven days after brain trauma. Although cell fractions were not used in this study, the translocation of TDP-43 from the nucleus to the cytoplasm of astrocytes was immunohistologically confirmed, suggesting the development of TDP-43 proteinopathy under these experimental conditions. In a focal model of controlled cortical impact (CCI), Wang et al. [39] also detected the decomposition of TDP-43 into 25 and 35 kDa fragments in cell lysates of the damaged cortex, seven days after trauma with a return to basal values 14 days after trauma, which was associated with the short-term impaired motor ability of tested experimental rats. Two months after the trauma, they recorded the accumulation of TDP-43 and its 25 and 35 kDa fragments and associated the obtained results with impaired learning and memory of experimental animals. In the described experimental design, it was proven that single focal TBI causes TDP-43 proteinopathy that could promote neurodegenerative changes [39]. Yang et al. [230] showed a redistribution of TDP-43 from the nucleus to the cytosol in the ipsilateral but not contralateral mouse cortex 24 hours after focal TBI caused by the CCI model and an increase in the levels of TDP-43 fragments that contribute to aggregation. In the same study, in a separate cohort of mice, overpressure blast-wave-induced brain injury caused an increased level of TDP-43 degradation products on the first and seventh day after TBI, and translocation of TDP-43 from frontal cortex neurons in both ipsilateral and contralateral cortex [230]. Saykally et al. [235], in a focal weight drop model on the exposed right side of the skull, demonstrated an increase of TDP-43 with the appearance of 25, 35, 60, and 100 kDa fragments in cell lysates 12 days after injury, which coincides with previous focal TBI studies.

In a single lateral fluid percussion injury (LFPI) model, which is widely considered as the best characterized preclinical model of combined TBI [236], three studies have been published thus far. In rats with moderate trauma, Wright et al. [223] immunohistologically demonstrated translocation of TDP-43 from the neuronal nucleus after seven days and 12 weeks after LFPI. Contrary to previously described human *post-mortem* studies, they also showed

an increase in phosphorylated TDP-43 at seven days and 12 weeks after trauma in cellular lysates of the cortex. In the mild mouse LFPI trauma [56], the 35 kDa TDP-43 products were found in cytosolic cell fractions, and 25 and 35 kDa ones in the nuclear fractions of the ipsilateral cortex, one and seven days after trauma. A total increase in TDP-43 and the presence of 25 and 35 kDa phosphorylated fragments were also detected in the nucleus, one and seven days after brain trauma which also opposes the results of *post-mortem* analyzes by Johnson et al. [152]. In a recent study by our group, pathological changes of TDP-43 were found on the 14th day after trauma, only in the hippocampus of the mice subjected to single moderate LFPI, but not repetitive mild traumas [224].

Studies of mild repetitive TBI, or concussion, show that TDP-43 proteinopathy is a common part of the pathological manifestation of the disease [137, 164, 166, 225]. McKee et al. [165] showed that 80% of examined retired boxers, football and hockey players had TDP-43 proteinopathy, which manifested as cytoplasmic inclusions of TDP-43 in neurons and glia, brainstem, basal ganglia, and diencephalon, medial temporal lobe, frontal and temporal cortex, and subcortical white matter. In some individuals, TDP-43 proteinopathy extends into the spinal cord and clinically manifests as motor neuron disease [165]. Although considered the most relevant, this study examined a relatively small group of athletes (71 respondents) of mentioned sports. Certainly, it is necessary to explore the incidence of TDP-43 inclusions in more detail, i.e., in other athletes of these and other sports, in which repetitive head trauma frequently occurs. In further research on TDP-43 proteinopathy, it is also necessary to include persons who have been exposed to physical violence and military personnel.

TDP-43 proteinopathy has been analyzed in a limited number of experimental repetitive TBI studies. As well as after a single TBI, the results vary significantly depending on the type and severity of the injury and the number of suffered traumas. Anderson et al. [237] performed a study of mild to severe repetitive TBI in the *Drosophila* model, and demonstrated the formation of TDP-43 positive stress granules whose density correlated with injury severity. Interestingly, TDP-43 positive stress granules were not identified after one trauma or 24 hours after the last repetitive trauma. They were only detected in a group of animals sacrificed immediately after the last repetitive trauma, which may suggest their removal and recovery. Animals with mutations in ALS-related genes had a more severe clinical presentation and higher mortality even after mild TBI, and an autophagy disorder prevented the removal of accumulated TDP-43 [237].

In a mouse focal mild repetitive CCI model, Zhang et al. [238] found an increase of TDP-43 immunohistochemically and in cell lysates of the cortex and hippocampus, eight days after the first of

three repetitive TBIs. The results were identical 30 days after the first trauma, which suggests the formation of aggregates. Saykally et al. [235] used a focal weight drop model, in which mice received five traumas over five days and observed an increase of TDP-43 in cell lysates of the ipsilateral cortex, acutely, on the third day after the last trauma. On days 30 and 60, a return to basal values is visible. In the ipsilateral hippocampus, an increase in TDP-43 expression was observed only on the day 60 of the last TBI. These results indicate the difference in TDP-43 pathology in the cortex and hippocampus, and the observed decrease in autophagy factors suggests that they are influenced by difficulties in removing excessive levels of TDP-43. In a study published by our group [226], in a model of repetitive diffuse TBI in mouse, TDP-43 translocation, fragmentation, and phosphorylation of the full length TDP-43 in the frontal cortex was found one day after the last brain trauma, with the return to basal values after three and seven days, respectively. In a rat repetitive TBI model caused by an explosion [239], a decrease in TDP-43 levels was observed after two traumas regardless of the severity and location of the trauma acquired. After three and four traumas, variations in the increased TDP-43 levels were observed depending on whether the trauma was applied laterally or from the front of the head and depending on the intensity of the trauma. These results indicate that a greater number of TBIs causes deregulation of TDP-43, which is the basis for the development of TDP-43 proteinopathy and consequent neurodegenerative pathology. A disorder of protein removal mechanisms after TBI is considered to be the cause [237].

Overall, the results of a relatively small number of available pre-clinical research are not in complete agreement with the results from the human samples, which is why further experimental and *post-mortem* studies of TDP-43 pathology after one and repetitive TBI are necessary. Current knowledge on TDP-43 proteinopathy after single and repetitive TBI is summarized in Table 2 [39, 56, 152, 153, 164-166, 220, 223-226, 230, 232, 234, 235, 237-239].

CONCLUSION

Based on the previous research, we can conclude that the best way to describe TBI is as polyopathy. Namely, human *post-mortem* studies have found combinations of amyloid, tau, Lewy bodies, and TDP-43 pathologies after both single and repetitive TBI. A single TBI does not indicate an absolute predisposition to develop Alzheimer's disease, just as not all individuals exposed to repetitive trauma will develop CTE symptoms. In addition, TBI can stimulate the development of other neurodegenerative conditions such as FTL and Parkinson's disease, and brain trauma, either single or repetitive, increases the incidence of these patho-

Table 2. Current knowledge on TDP-43 proteinopathy after single and repetitive traumatic brain injury available from *in vitro*, *in vivo*, and human studies

Single TBI (sTBI)	Repetitive TBI (rTBI)
<i>In vitro</i> models	
Accumulation of the P-TDP-43 and U-TDP-43 cytosolic aggregates in neurons [220]	Two TBIs increase cytosolic P-TDP43 two-fold and three TBIs three-fold in neurons [220]
<i>In vivo</i> models	
<i>Drosophyllae</i> model	
TDP-43 stress granules were not identified [237]	TDP-43 stress granules not found 24 h after the last rTBI; only detected in animals sacrificed immediately after the last repetitive trauma [237]
Blast TBI	
Cortical TDP-43 translocation to cytoplasm 1 dpi with TDP-43 fragmentation 1 and 7 dpi in the cortex [230]	Decrease in the TDP-43 expression after two TBIs and an increase in the expression of TDP-43 after three or four TBIs in the injured cortex 1 dpi, depending on the site of trauma application [239]
Changes in the TDP-43 expression in the injured cortex 1 dpi only at 16 psi blast overpressure over side; TDP-43 changes in other single TBI severities not detected [239]	
Diffuse TBI	
P-TDP-43 granules not found in the motor cortex [232]	TDP-43 translocation in neurons and microglia; TDP-43 fragmentation 1 dpi with phosphorylation 1 and 3 dpi in the frontal cortex [226] TDP-43 translocation, fragmentation and phosphorylation changes not detected in the hippocampus 14 dpi [224]
Focal TBI	
P-TDP-43 inclusions in the motor cortex at 3 dpi [232]	Increased TDP-43 expression in the cortical and hippocampal tissue 8 dpi [238] P-TDP-43 inclusions in the motor cortex at 3 and 7 dpi [232]
TDP-43 fragmentation 3 and 7 dpi with decrease in total cell TDP-43 on 1, 3, 7 dpi; TDP-43 aggregates at 7 dpi in the cortical tissue with TDP-43 translocation in the astrocytes at 7 dpi [234]	
TDP-43 fragmentation at 7 dpi and accumulation of cytosolic TDP-43 and its fragments two mpi in the injured cortex [39]	TDP-43 increase at 3 dpi in the cortex and 60 dpi in the hippocampus [235]
TDP-43 translocation to cytoplasm at 1 dpi and TDP-43 fragmentation at 3 and 7 dpi in the ipsilateral cortex [230]	
Increase in TDP-43 expression and its fragmentation at 12 dpi in the ipsilateral cortex [235]	
Lateral fluid percussion injury (LFPI)	
TDP-43 translocation in the cortical neurons and formation of P-TDP-43 at 7 dpi and 12 wpi in the cortex [223]	<i>To the best our knowledge, such studies have not been conducted thus far.</i>
TDP-43 fragmentation and phosphorylation of fragments at 1 and 7 dpi in the cortex [56]	
TDP-43 translocation in the cortical microglia and neurons at 3 dpi with TDP-43 fragmentation; P-TDP-43 formation at 14 dpi in the ipsilateral hippocampus [224]	
Human studies	
Phosphorylated TDP-43 aggregates in 3/62 acute and long-term TBI survivors, increased cytoplasmic TDP-43 in 86.9% <i>post-mortem</i> samples of acute and 71.8% of long-term single TBI survivors [152]	TDP-43 proteinopathy in 80% of the 12 <i>post-mortem</i> samples of retired boxers, football and hockey players; cytoplasmic TDP-43 inclusions in neurons and glia [165]
TDP-43 immunoreactivity and cytoplasmic inclusions in a case of a single severe TBI with phosphorylated tau protein co-localized with TDP-43 [153]	Focal to widespread TDP-43 pathology found in 85% of 85 subjects with history of mild rTBI [164]
Nuclear phosphorylated TDP-43 fragments in patients surviving up to 3 days after TBI [56]	TDP-43 pathology with neuronal cytoplasmic inclusions detected in all <i>post-mortem</i> cases of retired football players [225] TDP-43 inclusions in neurons and glia in a case of CTE in a former football player [166]

P-TDP-43, phosphorylated TAR DNA binding protein 43; U-TDP-43, ubiquitinated TAR DNA binding protein 43; dpi, days post injury; wpi, weeks post injury; mpi, months post injury; TBI, traumatic brain injury; CTE, chronic traumatic encephalopathy.

logical conditions.

A significant role of neuroinflammatory processes and TDP-43 pathology has been revealed in the development of cognitive and neural changes after TBI. While most studies focus on the study of only single or repetitive trauma, the discrepancy in the available results suggests the importance of standardization in all experimental protocols in one type of injury. As TBI is a particularly heterogeneous type of injury, it is possible that, depending on the trauma model and injury intensity, there are differences in the cascade of reactions during secondary injury. Because of this, animal research needs to be conducted in different TBI models and conditions of different types of experimental TBI. It would be desirable to conduct this research within the same laboratories, so that the differences are based only on the applied brain trauma, and not on the sample processing.

ACKNOWLEDGEMENTS

We thank Mrs. Marina Jakovac, Mrs. Maja Rukavina, and Mrs. Tanja Mešanović for their expert and valued technical assistance. This work has been supported by the by the University of Rijeka under the project uniri-biomed-18-199 to KP.

REFERENCES

- Menon DK, Schwab K, Wright DW, Maas AI; Demographics and Clinical Assessment Working Group of the International and Interagency Initiative toward Common Data Elements for Research on Traumatic Brain Injury and Psychological Health (2010) Position statement: definition of traumatic brain injury. *Arch Phys Med Rehabil* 91:1637-1640.
- Ghajar J (2000) Traumatic brain injury. *Lancet* 356:923-929.
- Tagliaferri F, Compagnone C, Korsic M, Servadei F, Kraus J (2006) A systematic review of brain injury epidemiology in Europe. *Acta Neurochir (Wien)* 148:255-268.
- Peeters W, van den Brande R, Polinder S, Brazinova A, Steyerberg EW, Lingsma HF, Maas AI (2015) Epidemiology of traumatic brain injury in Europe. *Acta Neurochir (Wien)* 157:1683-1696.
- Feigin VL, Theadom A, Barker-Collo S, Starkey NJ, McPherson K, Kahan M, Dowell A, Brown P, Parag V, Kydd R, Jones K, Jones A, Ameratunga S; BIONIC Study Group (2013) Incidence of traumatic brain injury in New Zealand: a population-based study. *Lancet Neurol* 12:53-64.
- Matney C, Bowman K, Berwick D (2022) The scope and burden of traumatic brain injury. In: *Traumatic brain injury: a roadmap for accelerating progress* (Berwick D, Bowman K, Matney C, eds), pp 27-46. National Academies Press, Washington DC.
- Maas AIR, Menon DK, Adelson PD, Andelic N, Bell MJ, Belli A, Bragge P, Brazinova A, Büki A, Chesnut RM, Citerio G, Coburn M, Cooper DJ, Crowder AT, Czeiter E, Czosnyka M, Diaz-Arrastia R, Dreier JP, Duhaime AC, Ercole A, van Essen TA, Feigin VL, Gao G, Giacino J, Gonzalez-Lara LE, Gruen RL, Gupta D, Hartings JA, Hill S, Jiang JY, Ketharanathan N, Kompanje EJO, Lanyon L, Laureys S, Lecky F, Levin H, Lingsma HF, Maegele M, Majdan M, Manley G, Marsteller J, Mascia L, McFadyen C, Mondello S, Newcombe V, Palotie A, Parizel PM, Peul W, Piercy J, Polinder S, Puybasset L, Rasmussen TE, Rossaint R, Smielewski P, Söderberg J, Stanworth SJ, Stein MB, von Steinbüchel N, Stewart W, Steyerberg EW, Stocchetti N, Synnot A, Te Ao B, Tenovuo O, Theadom A, Tibboel D, Videtta W, Wang KKW, Williams WH, Wilson L, Yaffe K; InTBIR Participants and Investigators (2017) Traumatic brain injury: integrated approaches to improve prevention, clinical care, and research. *Lancet Neurol* 16:987-1048.
- Dixon KJ (2017) Pathophysiology of traumatic brain injury. *Phys Med Rehabil Clin N Am* 28:215-225.
- Zaloshnja E, Miller T, Langlois JA, Selassie AW (2008) Prevalence of long-term disability from traumatic brain injury in the civilian population of the United States, 2005. *J Head Trauma Rehabil* 23:394-400.
- Gururaj G (2002) Epidemiology of traumatic brain injuries: Indian scenario. *Neurol Res* 24:24-28.
- McMillan TM, Teasdale GM (2007) Death rate is increased for at least 7 years after head injury: a prospective study. *Brain* 130(Pt 10):2520-2527.
- Elser H, Gottesman RF, Walter AE, Coresh J, Diaz-Arrastia R, Mosley TH, Schneider ALC (2023) Head injury and long-term mortality risk in community-dwelling adults. *JAMA Neurol* 80:260-269.
- Cheng PL, Lin HY, Lee YK, Hsu CY, Lee CC, Su YC (2014) Higher mortality rates among the elderly with mild traumatic brain injury: a nationwide cohort study. *Scand J Trauma Resusc Emerg Med* 22:7.
- Harrison-Felix C, Whiteneck G, DeVivo M, Hammond FM, Jha A (2004) Mortality following rehabilitation in the traumatic brain injury model systems of care. *NeuroRehabilitation* 19:45-54.
- Abio A, Bovet P, Valentin B, Bärnighausen T, Shaikh MA, Posti JP, Lowery Wilson M (2021) Changes in mortality related to traumatic brain injuries in the Seychelles from 1989 to 2018. *Front Neurol* 12:720434.
- Brazinova A, Rehorcikova V, Taylor MS, Buckova V, Majdan M,

- Psota M, Peeters W, Feigin V, Theadom A, Holkovic L, Synnot A (2021) Epidemiology of traumatic brain injury in Europe: a living systematic review. *J Neurotrauma* 38:1411-1440.
17. Yattoo G, Tabish A (2008) The profile of head injuries and traumatic brain injury deaths in Kashmir. *J Trauma Manag Outcomes* 2:5.
 18. Nordström A, Edin BB, Lindström S, Nordström P (2013) Cognitive function and other risk factors for mild traumatic brain injury in young men: nationwide cohort study. *BMJ* 346:f723.
 19. Prins M, Greco T, Alexander D, Giza CC (2013) The pathophysiology of traumatic brain injury at a glance. *Dis Model Mech* 6:1307-1315.
 20. Teasdale G, Maas A, Lecky F, Manley G, Stocchetti N, Murray G (2014) The Glasgow Coma Scale at 40 years: standing the test of time. *Lancet Neurol* 13:844-854.
 21. Teasdale G, Jennett B (1974) Assessment of coma and impaired consciousness. A practical scale. *Lancet* 2:81-84.
 22. McGinn MJ, Povlishock JT (2016) Pathophysiology of traumatic brain injury. *Neurosurg Clin N Am* 27:397-407.
 23. Ono J, Yamaura A, Kubota M, Okimura Y, Isobe K (2001) Outcome prediction in severe head injury: analyses of clinical prognostic factors. *J Clin Neurosci* 8:120-123.
 24. Ponsford JL, Spitz G, McKenzie D (2016) Using post-traumatic amnesia to predict outcome after traumatic brain injury. *J Neurotrauma* 33:997-1004.
 25. Russell WR, Smith A (1961) Post-traumatic amnesia in closed head injury. *Arch Neurol* 5:4-17.
 26. Dewan MC, Rattani A, Gupta S, Baticulon RE, Hung YC, Punchak M, Agrawal A, Adeleye AO, Shrimel MG, Rubiano AM, Rosenfeld JV, Park KB (2018) Estimating the global incidence of traumatic brain injury. *J Neurosurg* 130:1080-1097.
 27. Semple BD, Lee S, Sadjadi R, Fritz N, Carlson J, Griep C, Ho V, Jang P, Lamb A, Popolizio B, Saini S, Bazarian JJ, Prins ML, Ferriero DM, Basso DM, Noble-Haesslein LJ (2015) Repetitive concussions in adolescent athletes - translating clinical and experimental research into perspectives on rehabilitation strategies. *Front Neurol* 6:69.
 28. Vile AR, Atkinson L (2017) Chronic traumatic encephalopathy: the cellular sequela to repetitive brain injury. *J Clin Neurosci* 41:24-29.
 29. DeKosky ST, Ikonovic MD, Gandy S (2010) Traumatic brain injury--football, warfare, and long-term effects. *N Engl J Med* 363:1293-1296.
 30. Ojo JO, Mouzon B, Algamil M, Leary P, Lynch C, Abdullah L, Evans J, Mullan M, Bachmeier C, Stewart W, Crawford F (2016) Chronic repetitive mild traumatic brain injury results in reduced cerebral blood flow, axonal injury, gliosis, and increased T-tau and tau oligomers. *J Neuropathol Exp Neurol* 75:636-655.
 31. Roberts GW, Whitwell HL, Acland PR, Bruton CJ (1990) Dementia in a punch-drunk wife. *Lancet* 335:918-919.
 32. Ziemann G, Bridwell A, Cárdenas JF (2017) Traumatic brain injury in domestic violence victims: a retrospective study at the Barrow Neurological Institute. *J Neurotrauma* 34:876-880.
 33. Kamins J, Giza CC (2016) Concussion-mild traumatic brain injury: recoverable injury with potential for serious sequelae. *Neurosurg Clin N Am* 27:441-452.
 34. McCrory P, Meeuwisse WH, Kutcher JS, Jordan BD, Gardner A (2013) What is the evidence for chronic concussion-related changes in retired athletes: behavioural, pathological and clinical outcomes? *Br J Sports Med* 47:327-330.
 35. Masel BE, DeWitt DS (2010) Traumatic brain injury: a disease process, not an event. *J Neurotrauma* 27:1529-1540.
 36. Azouvi P, Arnould A, Dromer E, Vallat-Azouvi C (2017) Neuropsychology of traumatic brain injury: an expert overview. *Rev Neurol (Paris)* 173:461-472.
 37. Yasseen B, Colantonio A, Ratcliff G (2008) Prescription medication use in persons many years following traumatic brain injury. *Brain Inj* 22:752-757.
 38. Masel BE, Scheibel RS, Kimbark T, Kuna ST (2001) Excessive daytime sleepiness in adults with brain injuries. *Arch Phys Med Rehabil* 82:1526-1532.
 39. Wang HK, Lee YC, Huang CY, Liliang PC, Lu K, Chen HJ, Li YC, Tsai KJ (2015) Traumatic brain injury causes frontotemporal dementia and TDP-43 proteolysis. *Neuroscience* 300:94-103.
 40. McKee AC, Cantu RC, Nowinski CJ, Hedley-Whyte ET, Gavett BE, Budson AE, Santini VE, Lee HS, Kubilus CA, Stern RA (2009) Chronic traumatic encephalopathy in athletes: progressive tauopathy after repetitive head injury. *J Neuropathol Exp Neurol* 68:709-735.
 41. Schneider HJ, Kreitschmann-Andermahr I, Ghigo E, Stalla GK, Agha A (2007) Hypothalamopituitary dysfunction following traumatic brain injury and aneurysmal subarachnoid hemorrhage: a systematic review. *JAMA* 298:1429-1438.
 42. *Lancet Neurology* (2012) The changing landscape of traumatic brain injury research. *Lancet Neurol* 11:651.
 43. Agha A, Thompson CJ (2005) High risk of hypogonadism after traumatic brain injury: clinical implications. *Pituitary* 8:245-249.
 44. Safaz I, Alaca R, Yasar E, Tok F, Yilmaz B (2008) Medical complications, physical function and communication skills

- in patients with traumatic brain injury: a single centre 5-year experience. *Brain Inj* 22:733-739.
45. Elovic EP, Simone LK, Zafonte R (2004) Outcome assessment for spasticity management in the patient with traumatic brain injury: the state of the art. *J Head Trauma Rehabil* 19:155-177.
 46. Galgano M, Toshkezi G, Qiu X, Russell T, Chin L, Zhao LR (2017) Traumatic brain injury: current treatment strategies and future endeavors. *Cell Transplant* 26:1118-1130.
 47. Kaur P, Sharma S (2018) Recent advances in pathophysiology of traumatic brain injury. *Curr Neuropharmacol* 16:1224-1238.
 48. Dash HH, Chavali S (2018) Management of traumatic brain injury patients. *Korean J Anesthesiol* 71:12-21.
 49. Andriessen TM, Jacobs B, Vos PE (2010) Clinical characteristics and pathophysiological mechanisms of focal and diffuse traumatic brain injury. *J Cell Mol Med* 14:2381-2392.
 50. Mustafa AG, Alshboul OA (2013) Pathophysiology of traumatic brain injury. *Neurosciences (Riyadh)* 18:222-234.
 51. Farkas O, Lifshitz J, Povlishock JT (2006) Mechanoporation induced by diffuse traumatic brain injury: an irreversible or reversible response to injury? *J Neurosci* 26:3130-3140.
 52. Singleton RH, Zhu J, Stone JR, Povlishock JT (2002) Traumatically induced axotomy adjacent to the soma does not result in acute neuronal death. *J Neurosci* 22:791-802.
 53. Meythaler JM, Peduzzi JD, Eleftheriou E, Novack TA (2001) Current concepts: diffuse axonal injury-associated traumatic brain injury. *Arch Phys Med Rehabil* 82:1461-1471.
 54. Su E, Bell M (2016) Diffuse axonal injury. In: *Translational research in traumatic brain injury* (Laskowitz D, Grant G, eds), pp 41-84. CRC Press/Taylor and Francis Group, Boca Raton, FL.
 55. Bazarian JJ, Blyth B, Cimpello L (2006) Bench to bedside: evidence for brain injury after concussion--looking beyond the computed tomography scan. *Acad Emerg Med* 13:199-214.
 56. Tan XL, Sun M, Brady RD, Liu S, Llanos R, Cheung S, Wright DK, Casillas-Espinosa PM, Sashindranath M, O'Brien TJ, McDonald SJ, Turner BJ, Shultz SR (2019) Transactive response DNA-binding protein 43 abnormalities after traumatic brain injury. *J Neurotrauma* 36:87-99.
 57. Jassam YN, Izzy S, Whalen M, McGavern DB, El Khoury J (2017) Neuroimmunology of traumatic brain injury: time for a paradigm shift. *Neuron* 95:1246-1265.
 58. Johnson VE, Stewart JE, Begbie FD, Trojanowski JQ, Smith DH, Stewart W (2013) Inflammation and white matter degeneration persist for years after a single traumatic brain injury. *Brain* 136(Pt 1):28-42.
 59. Marklund N, Hillered L (2011) Animal modelling of traumatic brain injury in preclinical drug development: where do we go from here? *Br J Pharmacol* 164:1207-1229.
 60. Bramlett HM, Dietrich WD (2004) Pathophysiology of cerebral ischemia and brain trauma: similarities and differences. *J Cereb Blood Flow Metab* 24:133-150.
 61. Edwards G 3rd, Moreno-Gonzalez I, Soto C (2017) Amyloid-beta and tau pathology following repetitive mild traumatic brain injury. *Biochem Biophys Res Commun* 483:1137-1142.
 62. Ziebell JM, Morganti-Kossmann MC (2010) Involvement of pro- and anti-inflammatory cytokines and chemokines in the pathophysiology of traumatic brain injury. *Neurotherapeutics* 7:22-30.
 63. Schröder ML, Muizelaar JP, Fatouros PP, Kuta AJ, Choi SC (1998) Regional cerebral blood volume after severe head injury in patients with regional cerebral ischemia. *Neurosurgery* 42:1276-1281.
 64. Schwarzmaier SM, Kim SW, Trabold R, Plesnila N (2010) Temporal profile of thrombogenesis in the cerebral microcirculation after traumatic brain injury in mice. *J Neurotrauma* 27:121-130.
 65. von Oettingen G, Bergholt B, Gyldensted C, Astrup J (2002) Blood flow and ischemia within traumatic cerebral contusions. *Neurosurgery* 50:781-788.
 66. Blennow K, Hardy J, Zetterberg H (2012) The neuropathology and neurobiology of traumatic brain injury. *Neuron* 76:886-899.
 67. Spain A, Daumas S, Lifshitz J, Rhodes J, Andrews PJ, Horsburgh K, Fowler JH (2010) Mild fluid percussion injury in mice produces evolving selective axonal pathology and cognitive deficits relevant to human brain injury. *J Neurotrauma* 27:1429-1438.
 68. Keating CE, Cullen DK (2021) Mechanosensation in traumatic brain injury. *Neurobiol Dis* 148:105210.
 69. Barkhoudarian G, Hovda DA, Giza CC (2011) The molecular pathophysiology of concussive brain injury. *Clin Sports Med* 30:33-48, vii-iii.
 70. Ladak AA, Enam SA, Ibrahim MT (2019) A review of the molecular mechanisms of traumatic brain injury. *World Neurosurg* 131:126-132.
 71. Katayama Y, Becker DP, Tamura T, Hovda DA (1990) Massive increases in extracellular potassium and the indiscriminate release of glutamate following concussive brain injury. *J Neurosurg* 73:889-900.
 72. Kawamata T, Katayama Y, Hovda DA, Yoshino A, Becker DP (1992) Administration of excitatory amino acid antagonists via microdialysis attenuates the increase in glucose utilization seen following concussive brain injury. *J Cereb Blood Flow*

- Metab 12:12-24.
73. Osteen CL, Moore AH, Prins ML, Hovda DA (2001) Age-dependency of 45calcium accumulation following lateral fluid percussion: acute and delayed patterns. *J Neurotrauma* 18:141-162.
 74. Peng TI, Jou MJ (2010) Oxidative stress caused by mitochondrial calcium overload. *Ann NY Acad Sci* 1201:183-188.
 75. Xiong Y, Gu Q, Peterson PL, Muizelaar JP, Lee CP (1997) Mitochondrial dysfunction and calcium perturbation induced by traumatic brain injury. *J Neurotrauma* 14:23-34.
 76. Wang K, Cui D, Gao L (2016) Traumatic brain injury: a review of characteristics, molecular basis and management. *Front Biosci (Landmark Ed)* 21:890-899.
 77. Postolache TT, Wadhawan A, Can A, Lowry CA, Woodbury M, Makkar H, Hoisington AJ, Scott AJ, Potocki E, Benros ME, Stiller JW (2020) Inflammation in traumatic brain injury. *J Alzheimers Dis* 74:1-28.
 78. Simon DW, McGeachy MJ, Bayir H, Clark RS, Loane DJ, Kochanek PM (2017) The far-reaching scope of neuroinflammation after traumatic brain injury. *Nat Rev Neurol* 13:171-191.
 79. Shi K, Zhang J, Dong JF, Shi FD (2019) Dissemination of brain inflammation in traumatic brain injury. *Cell Mol Immunol* 16:523-530.
 80. Russo MV, McGavern DB (2016) Inflammatory neuroprotection following traumatic brain injury. *Science* 353:783-785.
 81. Raghupathi R (2004) Cell death mechanisms following traumatic brain injury. *Brain Pathol* 14:215-222.
 82. Akamatsu Y, Hanafy KA (2020) Cell death and recovery in traumatic brain injury. *Neurotherapeutics* 17:446-456.
 83. Stoica BA, Faden AI (2010) Cell death mechanisms and modulation in traumatic brain injury. *Neurotherapeutics* 7:3-12.
 84. Hinzman JM, DiNapoli VA, Mahoney EJ, Gerhardt GA, Hartings JA (2015) Spreading depolarizations mediate excitotoxicity in the development of acute cortical lesions. *Exp Neurol* 267:243-253.
 85. Louveau A, Smirnov I, Keyes TJ, Eccles JD, Rouhani SJ, Peske JD, Derecki NC, Castle D, Mandell JW, Lee KS, Harris TH, Kipnis J (2015) Structural and functional features of central nervous system lymphatic vessels. *Nature* 523:337-341.
 86. Corps KN, Roth TL, McGavern DB (2015) Inflammation and neuroprotection in traumatic brain injury. *JAMA Neurol* 72:355-362.
 87. Lagraoui M, Latoche JR, Cartwright NG, Sukumar G, Dalgard CL, Schaefer BC (2012) Controlled cortical impact and craniotomy induce strikingly similar profiles of inflammatory gene expression, but with distinct kinetics. *Front Neurol* 3:155.
 88. Gadani SP, Walsh JT, Lukens JR, Kipnis J (2015) Dealing with danger in the CNS: the response of the immune system to injury. *Neuron* 87:47-62.
 89. Roberts I, Yates D, Sandercock P, Farrell B, Wasserberg J, Lomas G, Cottingham R, Svoboda P, Brayley N, Mazairac G, Laloë V, Muñoz-Sánchez A, Arango M, Hartzenberg B, Khamis H, Yutthakasemsunt S, Komolafe E, Olladashi F, Yadav Y, Murillo-Cabezas F, Shakur H, Edwards P; CRASH trial collaborators (2004) Effect of intravenous corticosteroids on death within 14 days in 10008 adults with clinically significant head injury (MRC CRASH trial): randomised placebo-controlled trial. *Lancet* 364:1321-1328.
 90. Kelso ML, Gendelman HE (2014) Bridge between neuroimmunity and traumatic brain injury. *Curr Pharm Des* 20:4284-4298.
 91. Mira RG, Lira M, Cerpa W (2021) Traumatic brain injury: mechanisms of glial response. *Front Physiol* 12:740939.
 92. Liu HD, Li W, Chen ZR, Hu YC, Zhang DD, Shen W, Zhou ML, Zhu L, Hang CH (2013) Expression of the NLRP3 inflammasome in cerebral cortex after traumatic brain injury in a rat model. *Neurochem Res* 38:2072-2083.
 93. O'Brien WT, Pham L, Symons GF, Monif M, Shultz SR, McDonald SJ (2020) The NLRP3 inflammasome in traumatic brain injury: potential as a biomarker and therapeutic target. *J Neuroinflammation* 17:104.
 94. Karve IP, Taylor JM, Crack PJ (2016) The contribution of astrocytes and microglia to traumatic brain injury. *Br J Pharmacol* 173:692-702.
 95. Zhou Y, Shao A, Yao Y, Tu S, Deng Y, Zhang J (2020) Dual roles of astrocytes in plasticity and reconstruction after traumatic brain injury. *Cell Commun Signal* 18:62.
 96. Burda JE, Bernstein AM, Sofroniew MV (2016) Astrocyte roles in traumatic brain injury. *Exp Neurol* 275:305-315.
 97. Chiu CC, Liao YE, Yang LY, Wang JY, Tweedie D, Karnati HK, Greig NH, Wang JY (2016) Neuroinflammation in animal models of traumatic brain injury. *J Neurosci Methods* 272:38-49.
 98. Faulkner JR, Herrmann JE, Woo MJ, Tansey KE, Doan NB, Sofroniew MV (2004) Reactive astrocytes protect tissue and preserve function after spinal cord injury. *J Neurosci* 24:2143-2155.
 99. Wanner IB, Anderson MA, Song B, Levine J, Fernandez A, Gray-Thompson Z, Ao Y, Sofroniew MV (2013) Glial scar borders are formed by newly proliferated, elongated astrocytes that interact to corral inflammatory and fibrotic cells via STAT3-dependent mechanisms after spinal cord injury. *J Neurosci* 33:12870-12886.

100. Beschorner R, Dietz K, Schauer N, Mittelbronn M, Schluesener HJ, Trautmann K, Meyermann R, Simon P (2007) Expression of EAAT1 reflects a possible neuroprotective function of reactive astrocytes and activated microglia following human traumatic brain injury. *Histol Histopathol* 22:515-526.
101. Ikematsu K, Tsuda R, Kondo T, Nakasono I (2002) The expression of excitatory amino acid transporter 2 in traumatic brain injury. *Forensic Sci Int* 130:83-89.
102. van Landeghem FK, Weiss T, Oehmichen M, von Deimling A (2006) Decreased expression of glutamate transporters in astrocytes after human traumatic brain injury. *J Neurotrauma* 23:1518-1528.
103. Li YH, Zhang CL, Zhang XY, Zhou HX, Meng LL (2015) Effects of mild induced hypothermia on hippocampal connexin 43 and glutamate transporter 1 expression following traumatic brain injury in rats. *Mol Med Rep* 11:1991-1996.
104. Rao VL, Başkaya MK, Doğan A, Rothstein JD, Dempsey RJ (1998) Traumatic brain injury down-regulates glial glutamate transporter (GLT-1 and GLAST) proteins in rat brain. *J Neurochem* 70:2020-2027.
105. Gupta RK, Prasad S (2016) Age-dependent alterations in the interactions of NF- κ B and N-myc with GLT-1/EAAT2 promoter in the pericontusional cortex of mice subjected to traumatic brain injury. *Mol Neurobiol* 53:3377-3388.
106. Gupta RK, Prasad S (2013) Early down regulation of the glial Kir4.1 and GLT-1 expression in pericontusional cortex of the old male mice subjected to traumatic brain injury. *Biogerontology* 14:531-541.
107. McMahan PJ, Panczykowski DM, Yue JK, Puccio AM, Inoue T, Sorani MD, Lingsma HF, Maas AI, Valadka AB, Yuh EL, Mukherjee P, Manley GT, Okonkwo DO; TRACK-TBI Investigators (2015) Measurement of the glial fibrillary acidic protein and its breakdown products GFAP-BDP biomarker for the detection of traumatic brain injury compared to computed tomography and magnetic resonance imaging. *J Neurotrauma* 32:527-533.
108. Morrison H, Young K, Qureshi M, Rowe RK, Lifshitz J (2017) Quantitative microglia analyses reveal diverse morphologic responses in the rat cortex after diffuse brain injury. *Sci Rep* 7:13211.
109. Loane DJ, Kumar A (2016) Microglia in the TBI brain: the good, the bad, and the dysregulated. *Exp Neurol* 275:316-327.
110. Loane DJ, Kumar A, Stoica BA, Cabatbat R, Faden AI (2014) Progressive neurodegeneration after experimental brain trauma: association with chronic microglial activation. *J Neuropathol Exp Neurol* 73:14-29.
111. Salter MW, Stevens B (2017) Microglia emerge as central players in brain disease. *Nat Med* 23:1018-1027.
112. Donat CK, Scott G, Gentleman SM, Sastre M (2017) Microglial activation in traumatic brain injury. *Front Aging Neurosci* 9:208.
113. Xu H, Wang Z, Li J, Wu H, Peng Y, Fan L, Chen J, Gu C, Yan F, Wang L, Chen G (2017) The polarization states of microglia in TBI: a new paradigm for pharmacological intervention. *Neural Plast* 2017:5405104.
114. Izzy S, Liu Q, Fang Z, Lule S, Wu L, Chung JY, Sarro-Schwartz A, Brown-Whalen A, Perner C, Hickman SE, Kaplan DL, Patsopoulos NA, El Khoury J, Whalen MJ (2019) Time-dependent changes in microglia transcriptional networks following traumatic brain injury. *Front Cell Neurosci* 13:307.
115. de Rivero Vaccari JP, Brand F 3rd, Adamczak S, Lee SW, Perez-Barcena J, Wang MY, Bullock MR, Dietrich WD, Keane RW (2016) Exosome-mediated inflammasome signaling after central nervous system injury. *J Neurochem* 136 Suppl 1:39-48.
116. Nonaka M, Chen XH, Pierce JE, Leoni MJ, McIntosh TK, Wolf JA, Smith DH (1999) Prolonged activation of NF- κ B following traumatic brain injury in rats. *J Neurotrauma* 16:1023-1034.
117. Block ML, Zecca L, Hong JS (2007) Microglia-mediated neurotoxicity: uncovering the molecular mechanisms. *Nat Rev Neurosci* 8:57-69.
118. Dresselhaus EC, Meffert MK (2019) Cellular specificity of NF- κ B function in the nervous system. *Front Immunol* 10:1043.
119. Lam AG, Koppal T, Akama KT, Guo L, Craft JM, Samy B, Schavocky JP, Watterson DM, Van Eldik LJ (2001) Mechanism of glial activation by S100B: involvement of the transcription factor NF κ B. *Neurobiol Aging* 22:765-772.
120. Frakes AE, Ferraiuolo L, Haidet-Phillips AM, Schmelzer L, Braun L, Miranda CJ, Ladner KJ, Bevan AK, Foust KD, Godbout JP, Popovich PG, Guttridge DC, Kaspar BK (2014) Microglia induce motor neuron death via the classical NF- κ B pathway in amyotrophic lateral sclerosis. *Neuron* 81:1009-1023.
121. Bellander BM, Singhrao SK, Ohlsson M, Mattsson P, Svensson M (2001) Complement activation in the human brain after traumatic head injury. *J Neurotrauma* 18:1295-1311.
122. Alawieh A, Langley EF, Weber S, Adkins D, Tomlinson S (2018) Identifying the role of complement in triggering neuroinflammation after traumatic brain injury. *J Neurosci* 38:2519-2532.
123. Clausen F, Lorant T, Lewén A, Hillered L (2007) T lymphocyte trafficking: a novel target for neuroprotection in traumatic

- brain injury. *J Neurotrauma* 24:1295-1307.
124. Ling C, Sandor M, Suresh M, Fabry Z (2006) Traumatic injury and the presence of antigen differentially contribute to T-cell recruitment in the CNS. *J Neurosci* 26:731-741.
 125. Ramlackhansingh AF, Brooks DJ, Greenwood RJ, Bose SK, Turkheimer FE, Kinnunen KM, Gentleman S, Heckemann RA, Gunanayagam K, Gelsa G, Sharp DJ (2011) Inflammation after trauma: microglial activation and traumatic brain injury. *Ann Neurol* 70:374-383.
 126. Gentleman SM, Leclercq PD, Moyes L, Graham DI, Smith C, Griffin WS, Nicoll JA (2004) Long-term intracerebral inflammatory response after traumatic brain injury. *Forensic Sci Int* 146:97-104.
 127. Perry VH, Nicoll JA, Holmes C (2010) Microglia in neurodegenerative disease. *Nat Rev Neurol* 6:193-201.
 128. Sotosek Tokmadzic V, Laskarin G, Mahmutefendic H, Lucin P, Mrakovic-Sutic I, Zupan Z, Sustic A (2012) Expression of cytolytic protein-perforin in peripheral blood lymphocytes in severe traumatic brain injured patients. *Injury* 43:624-631.
 129. Witcher KG, Eiferman DS, Godbout JP (2015) Priming the inflammatory pump of the CNS after traumatic brain injury. *Trends Neurosci* 38:609-620.
 130. Saber M, Giordano KR, Hur Y, Ortiz JB, Morrison H, Godbout JP, Murphy SM, Lifshitz J, Rowe RK (2020) Acute peripheral inflammation and post-traumatic sleep differ between sexes after experimental diffuse brain injury. *Eur J Neurosci* 52:2791-2814.
 131. Schmidt RH, Grady MS (1993) Regional patterns of blood-brain barrier breakdown following central and lateral fluid percussion injury in rodents. *J Neurotrauma* 10:415-430.
 132. Ritzel RM, Doran SJ, Barrett JP, Henry RJ, Ma EL, Faden AI, Loane DJ (2018) Chronic alterations in systemic immune function after traumatic brain injury. *J Neurotrauma* 35:1419-1436.
 133. Schwulst SJ, Trahanas DM, Saber R, Perlman H (2013) Traumatic brain injury-induced alterations in peripheral immunity. *J Trauma Acute Care Surg* 75:780-788.
 134. Juengst SB, Kumar RG, Arenth PM, Wagner AK (2014) Exploratory associations with tumor necrosis factor- α , disinhibition and suicidal endorsement after traumatic brain injury. *Brain Behav Immun* 41:134-143.
 135. Kumar RG, Boles JA, Wagner AK (2015) Chronic inflammation after severe traumatic brain injury: characterization and associations with outcome at 6 and 12 months postinjury. *J Head Trauma Rehabil* 30:369-381.
 136. Faden AI, Loane DJ (2015) Chronic neurodegeneration after traumatic brain injury: Alzheimer disease, chronic traumatic encephalopathy, or persistent neuroinflammation? *Neurotherapeutics* 12:143-150.
 137. Smith DH, Johnson VE, Stewart W (2013) Chronic neuropathologies of single and repetitive TBI: substrates of dementia? *Nat Rev Neurol* 9:211-221.
 138. Blaylock RL, Maroon J (2011) Immunoexcitotoxicity as a central mechanism in chronic traumatic encephalopathy—a unifying hypothesis. *Surg Neurol Int* 2:107.
 139. Gill J, Mustapic M, Diaz-Arrastia R, Lange R, Gulyani S, Diehl T, Motamedi V, Osier N, Stern RA, Kapogiannis D (2018) Higher exosomal tau, amyloid-beta 42 and IL-10 are associated with mild TBIs and chronic symptoms in military personnel. *Brain Inj* 32:1277-1284.
 140. Lindqvist D, Wolkowitz OM, Mellon S, Yehuda R, Flory JD, Henn-Haase C, Bierer LM, Abu-Amara D, Coy M, Neylan TC, Makotkine I, Reus VI, Yan X, Taylor NM, Marmar CR, Dhabhar FS (2014) Proinflammatory milieu in combat-related PTSD is independent of depression and early life stress. *Brain Behav Immun* 42:81-88.
 141. Johnson VE, Stewart W, Smith DH (2012) Widespread τ and amyloid- β pathology many years after a single traumatic brain injury in humans. *Brain Pathol* 22:142-149.
 142. Johnson VE, Stewart W, Smith DH (2010) Traumatic brain injury and amyloid- β pathology: a link to Alzheimer's disease? *Nat Rev Neurosci* 11:361-370.
 143. Roberts GW, Gentleman SM, Lynch A, Graham DI (1991) β A4 amyloid protein deposition in brain after head trauma. *Lancet* 338:1422-1423.
 144. Roberts GW, Gentleman SM, Lynch A, Murray L, Landon M, Graham DI (1994) Beta amyloid protein deposition in the brain after severe head injury: implications for the pathogenesis of Alzheimer's disease. *J Neurol Neurosurg Psychiatry* 57:419-425.
 145. Kokiko-Cochran ON, Godbout JP (2018) The inflammatory continuum of traumatic brain injury and Alzheimer's disease. *Front Immunol* 9:672.
 146. Ikonomic MD, Uryu K, Abrahamson EE, Ciallella JR, Trojanowski JQ, Lee VM, Clark RS, Marion DW, Wisniewski SR, DeKosky ST (2004) Alzheimer's pathology in human temporal cortex surgically excised after severe brain injury. *Exp Neurol* 190:192-203.
 147. Li L, Bao Y, He S, Wang G, Guan Y, Ma D, Wu R, Wang P, Huang X, Tao S, Liu Q, Wang Y, Yang J (2015) The association between apolipoprotein E and functional outcome after traumatic brain injury: a meta-analysis. *Medicine (Baltimore)* 94:e2028.
 148. Chen XH, Johnson VE, Uryu K, Trojanowski JQ, Smith DH

- (2009) A lack of amyloid beta plaques despite persistent accumulation of amyloid beta in axons of long-term survivors of traumatic brain injury. *Brain Pathol* 19:214-223.
149. Kenney K, Iacono D, Edlow BL, Katz DI, Diaz-Arrastia R, Dams-O'Connor K, Daneshvar DH, Stevens A, Moreau AL, Tirrell LS, Varjabedian A, Yendiki A, van der Kouwe A, Marzayam A, McNab JA, Gordon WA, Fischl B, McKee AC, Perl DP (2018) Dementia after moderate-severe traumatic brain injury: coexistence of multiple proteinopathies. *J Neuropathol Exp Neurol* 77:50-63.
 150. Uryu K, Chen XH, Martinez D, Browne KD, Johnson VE, Graham DI, Lee VM, Trojanowski JQ, Smith DH (2007) Multiple proteins implicated in neurodegenerative diseases accumulate in axons after brain trauma in humans. *Exp Neurol* 208:185-192.
 151. Terry RD, Masliah E, Salmon DP, Butters N, DeTeresa R, Hill R, Hansen LA, Katzman R (1991) Physical basis of cognitive alterations in Alzheimer's disease: synapse loss is the major correlate of cognitive impairment. *Ann Neurol* 30:572-580.
 152. Johnson VE, Stewart W, Trojanowski JQ, Smith DH (2011) Acute and chronically increased immunoreactivity to phosphorylation-independent but not pathological TDP-43 after a single traumatic brain injury in humans. *Acta Neuropathol* 122:715-726.
 153. Tribett T, Erskine B, Bailey K, Brown T, Castellani RJ (2019) Chronic traumatic encephalopathy pathology after shotgun injury to the brain. *J Forensic Sci* 64:1248-1252.
 154. Farbota KD, Sodhi A, Bendlin BB, McLaren DG, Xu G, Rowley HA, Johnson SC (2012) Longitudinal volumetric changes following traumatic brain injury: a tensor-based morphometry study. *J Int Neuropsychol Soc* 18:1006-1018.
 155. Ross DE, Ochs AL, Seabaugh JM, Demark MF, Shrader CR, Marwitz JH, Havranek MD (2012) Progressive brain atrophy in patients with chronic neuropsychiatric symptoms after mild traumatic brain injury: a preliminary study. *Brain Inj* 26:1500-1509.
 156. Tomaiuolo F, Bivona U, Lerch JP, Di Paola M, Carlesimo GA, Ciurli P, Matteis M, Cecchetti L, Forcina A, Silvestro D, Azicnuda E, Sabatini U, Di Giacomo D, Caltagirone C, Petrides M, Formisano R (2012) Memory and anatomical change in severe non missile traumatic brain injury: ~1 vs. ~8 years follow-up. *Brain Res Bull* 87:373-382.
 157. Plassman BL, Havlik RJ, Steffens DC, Helms MJ, Newman TN, Drosdick D, Phillips C, Gau BA, Welsh-Bohmer KA, Burke JR, Guralnik JM, Breitner JC (2000) Documented head injury in early adulthood and risk of Alzheimer's disease and other dementias. *Neurology* 55:1158-1166.
 158. Tomaiuolo F, Carlesimo GA, Di Paola M, Petrides M, Fera F, Bonanni R, Formisano R, Pasqualetti P, Caltagirone C (2004) Gross morphology and morphometric sequelae in the hippocampus, fornix, and corpus callosum of patients with severe non-missile traumatic brain injury without macroscopically detectable lesions: a T1 weighted MRI study. *J Neurol Neurosurg Psychiatry* 75:1314-1322.
 159. Washington PM, Villapol S, Burns MP (2016) Polypathology and dementia after brain trauma: does brain injury trigger distinct neurodegenerative diseases, or should they be classified together as traumatic encephalopathy? *Exp Neurol* 275:381-388.
 160. LoBue C, Denney D, Hynan LS, Rossetti HC, Lacritz LH, Hart J, Womack KB, Woon FL, Cullum CM (2016) Self-reported traumatic brain injury and mild cognitive impairment: increased risk and earlier age of diagnosis. *J Alzheimers Dis* 51:727-736.
 161. McKee AC, Cairns NJ, Dickson DW, Folkerth RD, Keene CD, Litvan I, Perl DP, Stein TD, Vonsattel JP, Stewart W, Tripodis Y, Crary JE, Bieniek KF, Dams-O'Connor K, Alvarez VE, Gordon WA; TBI/CTE Group (2016) The first NINDS/NIBIB consensus meeting to define neuropathological criteria for the diagnosis of chronic traumatic encephalopathy. *Acta Neuropathol* 131:75-86.
 162. Yang C, Nag S, Xing G, Aggarwal NT, Schneider JA (2020) A clinicopathological report of a 93-year-old former street boxer with coexistence of chronic traumatic encephalopathy, Alzheimer's disease, dementia with lewy bodies, and hippocampal sclerosis with TDP-43 pathology. *Front Neurol* 11:42.
 163. Lee BG, Leavitt MJ, Bernick CB, Leger GC, Rabinovici G, Banks SJ (2018) A systematic review of positron emission tomography of tau, amyloid beta, and neuroinflammation in chronic traumatic encephalopathy: the evidence to date. *J Neurotrauma* 35:2015-2024.
 164. McKee AC, Stern RA, Nowinski CJ, Stein TD, Alvarez VE, Daneshvar DH, Lee HS, Wojtowicz SM, Hall G, Baugh CM, Riley DO, Kubilus CA, Cormier KA, Jacobs MA, Martin BR, Abraham CR, Ikezu T, Reichard RR, Wolozin BL, Budson AE, Goldstein LE, Kowall NW, Cantu RC (2013) The spectrum of disease in chronic traumatic encephalopathy. *Brain* 136(Pt 1):43-64.
 165. McKee AC, Gavett BE, Stern RA, Nowinski CJ, Cantu RC, Kowall NW, Perl DP, Hedley-Whyte ET, Price B, Sullivan C, Morin P, Lee HS, Kubilus CA, Daneshvar DH, Wulff M, Budson AE (2010) TDP-43 proteinopathy and motor neuron disease in chronic traumatic encephalopathy. *J Neuropathol Exp Neurol* 69:918-929.

166. Omalu B, Small GW, Bailes J, Ercoli LM, Merrill DA, Wong KP, Huang SC, Satyamurthy N, Hammers JL, Lee J, Fitzsimmons RP, Barrio JR (2018) Postmortem autopsy-confirmation of antemortem [F-18]FDDNP-PET scans in a football player with chronic traumatic encephalopathy. *Neurosurgery* 82:237-246.
167. McKee AC, Daneshvar DH, Alvarez VE, Stein TD (2014) The neuropathology of sport. *Acta Neuropathol* 127:29-51.
168. Baragi VM, Gattu R, Trifan G, Woodard JL, Meyers K, Halstead TS, Hipple E, Haacke EM, Benson RR (2022) Neuroimaging markers for determining former American football players at risk for Alzheimer's disease. *Neurotrauma Rep* 3:398-414.
169. Coughlin JM, Wang Y, Munro CA, Ma S, Yue C, Chen S, Aïran R, Kim PK, Adams AV, Garcia C, Higgs C, Sair HI, Sawa A, Smith G, Lyketsos CG, Caffo B, Kassiou M, Guilarte TR, Pomper MG (2015) Neuroinflammation and brain atrophy in former NFL players: an in vivo multimodal imaging pilot study. *Neurobiol Dis* 74:58-65.
170. Jordan BD, Jahre C, Hauser WA, Zimmerman RD, Zarrelli M, Lipsitz EC, Johnson V, Warren RF, Tsairis P, Folk FS (1992) CT of 338 active professional boxers. *Radiology* 185:509-512.
171. Omalu BI, DeKosky ST, Hamilton RL, Minster RL, Kamboh MI, Shakir AM, Wecht CH (2006) Chronic traumatic encephalopathy in a national football league player: part II. *Neurosurgery* 59:1086-1092.
172. Omalu B, Bailes J, Hamilton RL, Kamboh MI, Hammers J, Case M, Fitzsimmons R (2011) Emerging histomorphologic phenotypes of chronic traumatic encephalopathy in American athletes. *Neurosurgery* 69:173-183.
173. Omalu BI, DeKosky ST, Minster RL, Kamboh MI, Hamilton RL, Wecht CH (2005) Chronic traumatic encephalopathy in a national football league player. *Neurosurgery* 57:128-134.
174. Nowak LA, Smith GG, Reyes PF (2009) Dementia in a retired world boxing champion: case report and literature review. *Clin Neuropathol* 28:275-280.
175. Omalu BI, Fitzsimmons RP, Hammers J, Bailes J (2010) Chronic traumatic encephalopathy in a professional American wrestler. *J Forensic Nurs* 6:130-136.
176. Saing T, Dick M, Nelson PT, Kim RC, Cribbs DH, Head E (2012) Frontal cortex neuropathology in dementia pugilistica. *J Neurotrauma* 29:1054-1070.
177. Jordan BD, Matser EJ, Zimmerman RD, Zazula T (1996) Sparring and cognitive function in professional boxers. *Phys Sportsmed* 24:87-98.
178. Fjell AM, Walhovd KB, Fennema-Notestine C, McEvoy LK, Hagler DJ, Holland D, Brewer JB, Dale AM (2009) One-year brain atrophy evident in healthy aging. *J Neurosci* 29:15223-15231.
179. Alosco ML, Mian AZ, Buch K, Farris CW, Uretsky M, Tripodis Y, Baucom Z, Martin B, Palmisano J, Puzo C, Ang TFA, Joshi P, Goldstein LE, Au R, Katz DI, Dwyer B, Daneshvar DH, Nowinski C, Cantu RC, Kowall NW, Huber BR, Alvarez VE, Stern RA, Stein TD, Killiany RJ, McKee AC, Mez J (2021) Structural MRI profiles and tau correlates of atrophy in autopsy-confirmed CTE. *Alzheimers Res Ther* 13:193.
180. Johnson VE, Stewart W, Arena JD, Smith DH (2017) Traumatic brain injury as a trigger of neurodegeneration. *Adv Neurobiol* 15:383-400.
181. Das JM, Dossani RH (2023) Cavum septum pellucidum [Internet]. StatPearls Publishing, Treasure Island, FL. Available from: <https://www.ncbi.nlm.nih.gov/books/NBK537048/>
182. Daneshvar DH, Goldstein LE, Kiernan PT, Stein TD, McKee AC (2015) Post-traumatic neurodegeneration and chronic traumatic encephalopathy. *Mol Cell Neurosci* 66(Pt B):81-90.
183. LoBue C, Schaffert J, Cullum CM, Peters ME, Didehban N, Hart J, White CL (2020) Clinical and neuropsychological profile of patients with dementia and chronic traumatic encephalopathy. *J Neurol Neurosurg Psychiatry* 91:586-592.
184. Fleminger S, Oliver DL, Lovestone S, Rabe-Hesketh S, Giora A (2003) Head injury as a risk factor for Alzheimer's disease: the evidence 10 years on; a partial replication. *J Neurol Neurosurg Psychiatry* 74:857-862.
185. Guo Z, Cupples LA, Kurz A, Auerbach SH, Volicer L, Chui H, Green RC, Sadovnick AD, Duara R, DeCarli C, Johnson K, Go RC, Growdon JH, Haines JL, Kukull WA, Farrer LA (2000) Head injury and the risk of AD in the MIRAGE study. *Neurology* 54:1316-1323.
186. Sultana R, Banks WA, Butterfield DA (2010) Decreased levels of PSD95 and two associated proteins and increased levels of BCL2 and caspase 3 in hippocampus from subjects with amnesic mild cognitive impairment: insights into their potential roles for loss of synapses and memory, accumulation of A β , and neurodegeneration in a prodromal stage of Alzheimer's disease. *J Neurosci Res* 88:469-477.
187. Gentleman SM, Greenberg BD, Savage MJ, Noori M, Newman SJ, Roberts GW, Griffin WS, Graham DI (1997) A beta 42 is the predominant form of amyloid beta-protein in the brains of short-term survivors of head injury. *Neuroreport* 8:1519-1522.
188. Mehta KM, Ott A, Kalmijn S, Slooter AJ, van Duijn CM, Hofman A, Breteler MM (1999) Head trauma and risk of dementia and Alzheimer's disease: the Rotterdam study. *Neurology* 53:1959-1962.

189. Williams DB, Annegers JF, Kokmen E, O'Brien PC, Kurland LT (1991) Brain injury and neurologic sequelae: a cohort study of dementia, parkinsonism, and amyotrophic lateral sclerosis. *Neurology* 41:1554-1557.
190. Smith C, Graham DI, Murray LS, Nicoll JA (2003) Tau immunohistochemistry in acute brain injury. *Neuropathol Appl Neurobiol* 29:496-502.
191. Noy S, Krawitz S, Del Bigio MR (2016) Chronic traumatic encephalopathy-like abnormalities in a routine neuropathology service. *J Neuropathol Exp Neurol* 75:1145-1154.
192. Puvenna V, Engeler M, Banjara M, Brennan C, Schreiber P, Dadas A, Bahrami A, Solanki J, Bandyopadhyay A, Morris JK, Bernick C, Ghosh C, Rapp E, Bazarian JJ, Janigro D (2016) Is phosphorylated tau unique to chronic traumatic encephalopathy? Phosphorylated tau in epileptic brain and chronic traumatic encephalopathy. *Brain Res* 1630:225-240.
193. Ling H, Holton JL, Shaw K, Davey K, Lashley T, Revesz T (2015) Histological evidence of chronic traumatic encephalopathy in a large series of neurodegenerative diseases. *Acta Neuropathol* 130:891-893.
194. Martland HS (1928) Punch drunk. *JAMA* 91:1103-1107.
195. Millsbaugh JA (1937) Dementia pugilistica. *U S Nav Med Bull* 35:297-303.
196. Fusco A, Olowofela B, Dagra A, Hatem R, Pierre K, Siyanaki MRH, Lucke-Wold B (2022) Management of neuropsychiatric symptoms for chronic traumatic encephalopathy. *Med-Press Psychiatry Behav Sci* 1:202209003.
197. Corsellis JA, Bruton CJ, Freeman-Browne D (1973) The aftermath of boxing. *Psychol Med* 3:270-303.
198. Hof PR, Knabe R, Bovier P, Bouras C (1991) Neuropathological observations in a case of autism presenting with self-injury behavior. *Acta Neuropathol* 82:321-326.
199. Quintin S, Sorrentino ZA, Mehkri Y, Sriram S, Weisman S, Davidson CG, Lloyd GM, Sung E, Figg JW, Lucke-Wold B (2022) Proteinopathies and neurotrauma: update on degenerative cascades. *JSM Neurosurg Spine* 9:1106.
200. Chen-Plotkin AS, Lee VM, Trojanowski JQ (2010) TAR DNA-binding protein 43 in neurodegenerative disease. *Nat Rev Neurol* 6:211-220.
201. Mackenzie IR, Rademakers R (2008) The role of transactive response DNA-binding protein-43 in amyotrophic lateral sclerosis and frontotemporal dementia. *Curr Opin Neurol* 21:693-700.
202. Ratti A, Buratti E (2016) Physiological functions and pathology of TDP-43 and FUS/TLS proteins. *J Neurochem* 138 Suppl 1:95-111.
203. Ravanidis S, Kattan FG, Doxakis E (2018) Unraveling the pathways to neuronal homeostasis and disease: mechanistic insights into the role of RNA-binding proteins and associated factors. *Int J Mol Sci* 19:2280.
204. Wong CE, Jin LW, Chu YP, Wei WY, Ho PC, Tsai KJ (2021) TDP-43 proteinopathy impairs mRNP granule mediated postsynaptic translation and mRNA metabolism. *Theranostics* 11:330-345.
205. Polymenidou M, Lagier-Tourenne C, Hutt KR, Huelga SC, Moran J, Liang TY, Ling SC, Sun E, Wancewicz E, Mazur C, Kordasiewicz H, Sedaghat Y, Donohue JP, Shiue L, Bennett CF, Yeo GW, Cleveland DW (2011) Long pre-mRNA depletion and RNA missplicing contribute to neuronal vulnerability from loss of TDP-43. *Nat Neurosci* 14:459-468.
206. Koza P, Beroun A, Konopka A, Górkiewicz T, Bijoch L, Torres JC, Bulska E, Knapska E, Kaczmarek L, Konopka W (2019) Neuronal TDP-43 depletion affects activity-dependent plasticity. *Neurobiol Dis* 130:104499.
207. Ling SC (2018) Synaptic paths to neurodegeneration: the emerging role of TDP-43 and FUS in synaptic functions. *Neural Plast* 2018:8413496.
208. Sheng M, Sabatini BL, Südhof TC (2012) Synapses and Alzheimer's disease. *Cold Spring Harb Perspect Biol* 4:a005777.
209. Bellucci A, Zaltieri M, Navarria L, Grigoletto J, Missale C, Spano P (2012) From α -synuclein to synaptic dysfunctions: new insights into the pathophysiology of Parkinson's disease. *Brain Res* 1476:183-202.
210. Prasad A, Bharathi V, Sivalingam V, Girdhar A, Patel BK (2019) Molecular mechanisms of TDP-43 misfolding and pathology in amyotrophic lateral sclerosis. *Front Mol Neurosci* 12:25.
211. Talbott EO, Malek AM, Lacomis D (2016) The epidemiology of amyotrophic lateral sclerosis. *Handb Clin Neurol* 138:225-238.
212. Lee EB, Lee VM, Trojanowski JQ (2011) Gains or losses: molecular mechanisms of TDP43-mediated neurodegeneration. *Nat Rev Neurosci* 13:38-50.
213. Geser F, Lee VM, Trojanowski JQ (2010) Amyotrophic lateral sclerosis and frontotemporal lobar degeneration: a spectrum of TDP-43 proteinopathies. *Neuropathology* 30:103-112.
214. Mackenzie IR, Rademakers R, Neumann M (2010) TDP-43 and FUS in amyotrophic lateral sclerosis and frontotemporal dementia. *Lancet Neurol* 9:995-1007.
215. Kapeli K, Martinez FJ, Yeo GW (2017) Genetic mutations in RNA-binding proteins and their roles in ALS. *Hum Genet* 136:1193-1214.
216. Huang CC, Bose JK, Majumder P, Lee KH, Huang JT, Huang JK, Shen CK (2014) Metabolism and mis-metabolism of the neuropathological signature protein TDP-43. *J Cell Sci* 127(Pt

- 14):3024-3038.
217. Johnson BS, Snead D, Lee JJ, McCaffery JM, Shorter J, Gitler AD (2009) TDP-43 is intrinsically aggregation-prone, and amyotrophic lateral sclerosis-linked mutations accelerate aggregation and increase toxicity. *J Biol Chem* 284:20329-20339.
218. Correia AS, Patel P, Dutta K, Julien JP (2015) Inflammation induces TDP-43 mislocalization and aggregation. *PLoS One* 10:e0140248.
219. Gao F, Hu M, Zhang J, Hashem J, Chen C (2022) TDP-43 drives synaptic and cognitive deterioration following traumatic brain injury. *Acta Neuropathol* 144:187-210.
220. Jayakumar AR, Tong XY, Shamaladevi N, Barcelona S, Gaidosh G, Agarwal A, Norenberg MD (2017) Defective synthesis and release of astrocytic thrombospondin-1 mediates the neuronal TDP-43 proteinopathy, resulting in defects in neuronal integrity associated with chronic traumatic encephalopathy: in vitro studies. *J Neurochem* 140:645-661.
221. Li J, Gould TD, Yuan P, Manji HK, Chen G (2003) Post-mortem interval effects on the phosphorylation of signaling proteins. *Neuropsychopharmacology* 28:1017-1025.
222. Franz CK, Joshi D, Daley EL, Grant RA, Dalamagkas K, Leung A, Finan JD, Kiskinis E (2019) Impact of traumatic brain injury on amyotrophic lateral sclerosis: from bedside to bench. *J Neurophysiol* 122:1174-1185.
223. Wright DK, Liu S, van der Poel C, McDonald SJ, Brady RD, Taylor L, Yang L, Gardner AJ, Ordidge R, O'Brien TJ, Johnston LA, Shultz SR (2017) Traumatic brain injury results in cellular, structural and functional changes resembling motor neuron disease. *Cereb Cortex* 27:4503-4515.
224. Janković T, Dolenc P, Rajič Bumber J, Gržeta N, Kriz J, Župan G, Pilipović K (2021) Differential expression patterns of TDP-43 in single moderate versus repetitive mild traumatic brain injury in mice. *Int J Mol Sci* 22:12211.
225. Ling H, Morris HR, Neal JW, Lees AJ, Hardy J, Holton JL, Revesz T, Williams DD (2017) Mixed pathologies including chronic traumatic encephalopathy account for dementia in retired association football (soccer) players. *Acta Neuropathol* 133:337-352.
226. Rajič Bumber J, Pilipović K, Janković T, Dolenc P, Gržeta N, Kriz J, Župan G (2021) Repetitive traumatic brain injury is associated with TDP-43 alterations, neurodegeneration, and glial activation in mice. *J Neuropathol Exp Neurol* 80:2-14.
227. Dadas A, Washington J, Diaz-Arrastia R, Janigro D (2018) Biomarkers in traumatic brain injury (TBI): a review. *Neuropsychiatr Dis Treat* 14:2989-3000.
228. Hergenroeder GW, Redell JB, Moore AN, Dash PK (2008) Biomarkers in the clinical diagnosis and management of traumatic brain injury. *Mol Diagn Ther* 12:345-358.
229. Tsitsopoulos PP, Marklund N (2013) Amyloid- β peptides and tau protein as biomarkers in cerebrospinal and interstitial fluid following traumatic brain injury: a review of experimental and clinical studies. *Front Neurol* 4:79.
230. Yang Z, Lin F, Robertson CS, Wang KK (2014) Dual vulnerability of TDP-43 to calpain and caspase-3 proteolysis after neurotoxic conditions and traumatic brain injury. *J Cereb Blood Flow Metab* 34:1444-1452.
231. Williams SM, Peltz C, Yaffe K, Schulz P, Sierks MR (2018) CNS disease-related protein variants as blood-based biomarkers in traumatic brain injury. *Neurology* 91:702-709.
232. Wiesner D, Tar L, Linkus B, Chandrasekar A, Olde Heuvel F, Dupuis L, Tsao W, Wong PC, Ludolph A, Roselli F (2018) Reversible induction of TDP-43 granules in cortical neurons after traumatic injury. *Exp Neurol* 299(Pt A):15-25.
233. Flierl MA, Stahel PF, Beauchamp KM, Morgan SJ, Smith WR, Shohami E (2009) Mouse closed head injury model induced by a weight-drop device. *Nat Protoc* 4:1328-1337.
234. Huang CY, Lee YC, Li PC, Liliang PC, Lu K, Wang KW, Chang LC, Shiu LY, Chen MF, Sun YT, Wang HK (2017) TDP-43 proteolysis is associated with astrocyte reactivity after traumatic brain injury in rodents. *J Neuroimmunol* 313:61-68.
235. Saykally JN, Ratliff WA, Keeley KL, Pick CG, Mervis RF, Citron BA (2018) Repetitive mild closed head injury alters protein expression and dendritic complexity in a mouse model. *J Neurotrauma* 35:139-148.
236. Thompson HJ, Lifshitz J, Marklund N, Grady MS, Graham DI, Hovda DA, McIntosh TK (2005) Lateral fluid percussion brain injury: a 15-year review and evaluation. *J Neurotrauma* 22:42-75.
237. Anderson EN, Gochenaour L, Singh A, Grant R, Patel K, Watkins S, Wu JY, Pandey UB (2018) Traumatic injury induces stress granule formation and enhances motor dysfunctions in ALS/FTD models. *Hum Mol Genet* 27:1366-1381.
238. Zhang J, Teng Z, Song Y, Hu M, Chen C (2015) Inhibition of monoacylglycerol lipase prevents chronic traumatic encephalopathy-like neuropathology in a mouse model of repetitive mild closed head injury. *J Cereb Blood Flow Metab* 35:443-453.
239. Heyburn L, Abutarboush R, Goodrich S, Urioste R, Batuure A, Statz J, Wilder D, Ahlers ST, Long JB, Sajja VSSS (2019) Repeated low-level blast overpressure leads to endovascular disruption and alterations in TDP-43 and Piezo2 in a rat model of blast TBI. *Front Neurol* 10:766.